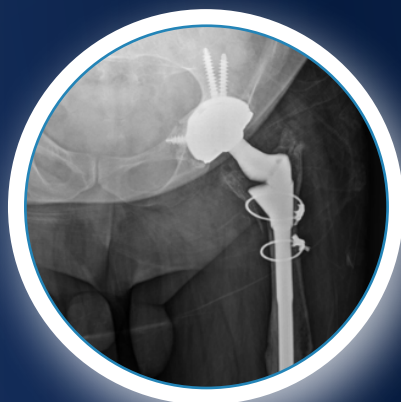

Medical Education Series

Total Hip Arthroplasty

Matthew Duffin, MD
Atrium Health
Rock Hill, South Carolina



PATIENT HISTORY

A 53 year old male with history of left Total Hip Arthroplasty (THA) at a young age due to congenital hip abnormalities. Patient presented initially with increasing pain and decreased ability to walk.

DIAGNOSIS

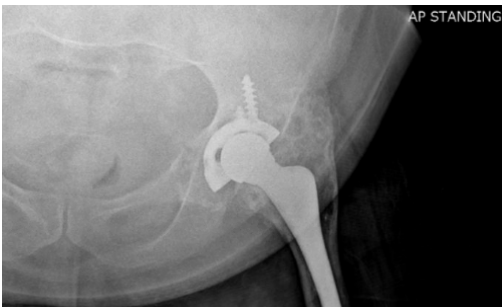
Pre-op x-rays revealed asymmetric poly wear, large amounts of osteolysis around the acetabular component and femoral stem with stem subsidence.

TREATMENT PLAN

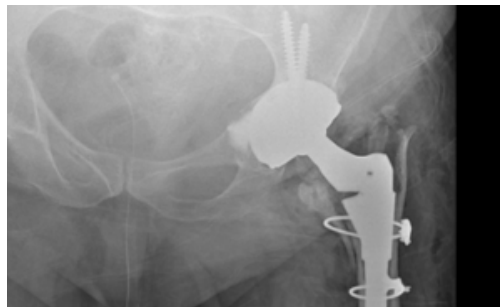Revision Total Hip Arthroplasty was performed. The medial contained acetabular bony defect was filled with 10mL of CERAMENT® BONE VOID FILLER through a screw hole in the cup, followed by screw fixation.

OUTCOME

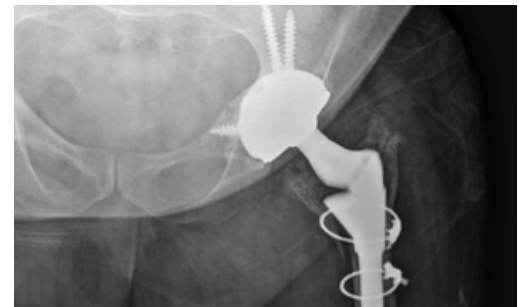
At three months post-op, CERAMENT® BVF has resorbed and some new bone formation in the bone void is evident. There is stable cup fixation and the patient is working back to baseline ambulatory status without pain.



Pre Op x-ray: Medial acetabular bone defect.



Post Op: CERAMENT® BVF is visible in the medial acetabular defect.



4 month Post op: New bone formation medial to the acetabular component with stable fixation.