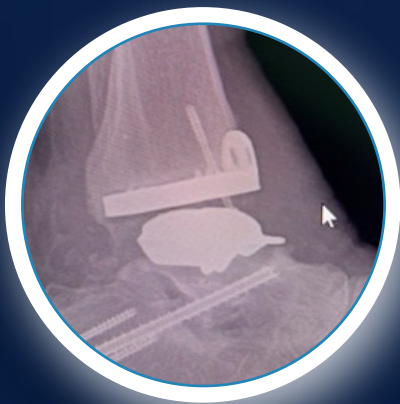

Medical Education Series

Revision Total Ankle Replacement

James M. Cottom DPM, FACFAS
Director, Florida Orthopedic Foot & Ankle Center Fellowship



PATIENT HISTORY

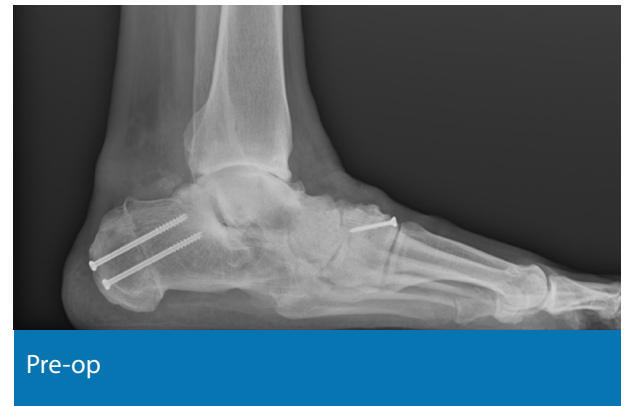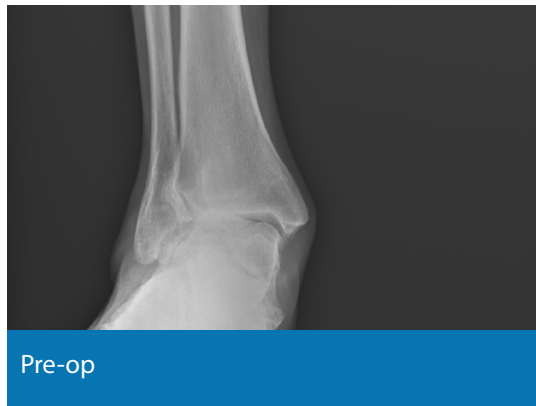A 60-year-old male presented with right ankle pain for >10 years. His past medical history was unremarkable. He had a previous flat foot reconstruction done 8 years prior. He was told by other surgeons that fusion was his only option but he is an avid walker and bike rider and wanted to retain motion in his ankle if possible.

DIAGNOSIS

End stage post-traumatic ankle arthritis with a slight valgus angulation. The ankle joint was reducible and the deltoid ligament was intact and functioning.

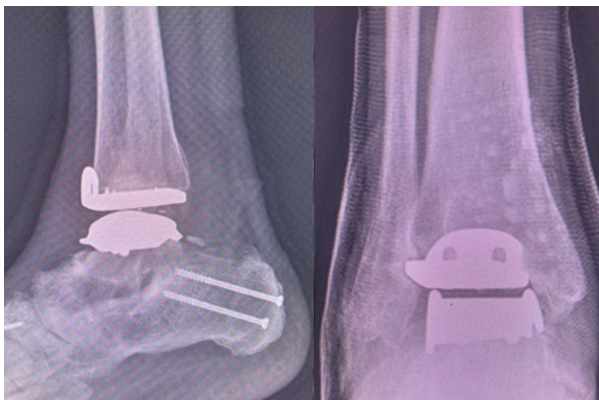
TREATMENT PLAN

- Achilles tendon lengthening
- Posterior capsule release
- Total ankle replacement
- Possible brostrom

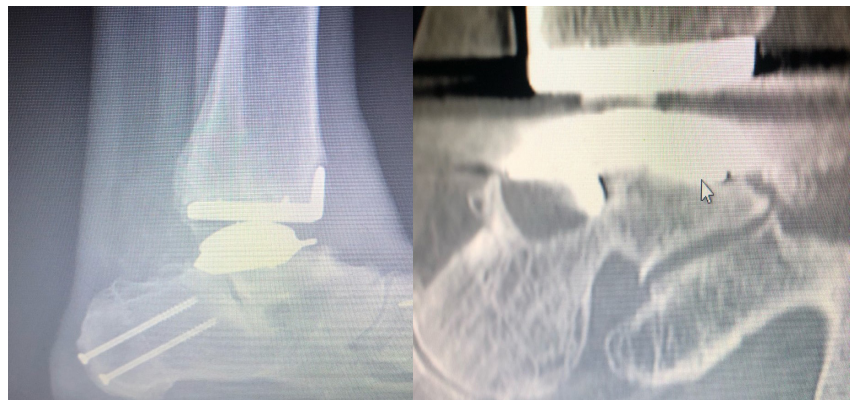


PRIMARY IMPLANT

The patient did well for the first 2 years after the ankle replacement. At his two year follow up, radiographs were taken and demonstrated subsidence of the talar component. The patient then informed us he recently started competitive trail racing on his mountain bike. He stated the trails were very rough and he has fallen a "few times." He also related some increased discomfort within the ankle after starting racing.



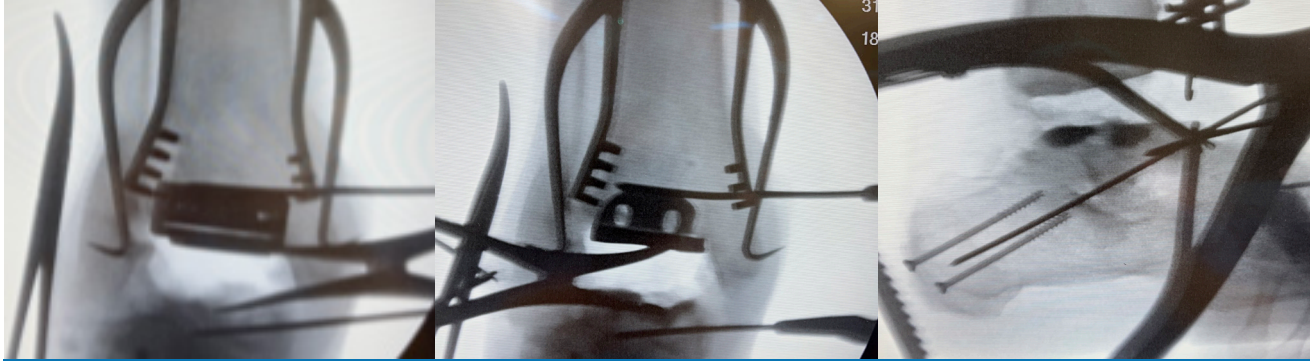1 year post-op from the index total ankle replacement.



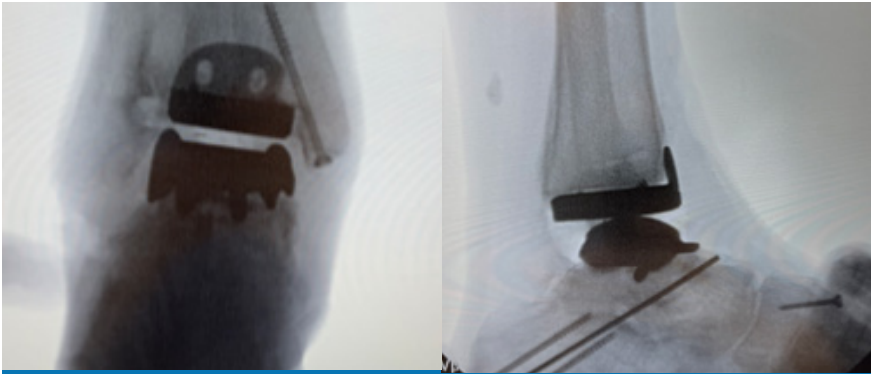
Lateral radiograph showing subsidence and posterior tilting of the talar component (left) and CT scan demonstrating large cysts forming around the anterior talar pegs.

REVISION

CERAMENT® BONE VOID FILLER was used to fill the posterior defect in the talus and the anterior peg holes in the talus (middle & right images). Fusion of the entire subtalar joint was not attempted, instead a “spotweld” was used to prevent compromising blood supply to the talus and risk AVN or failure.



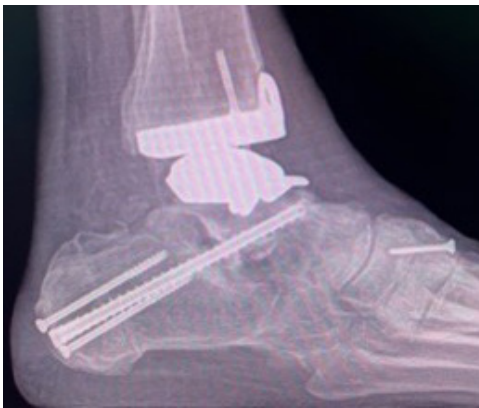Intra-op images showing explantation of the tibia and talar components with a tibial retractor. Note the large defect in the superior lateral talus from the talar implant loosening (left).



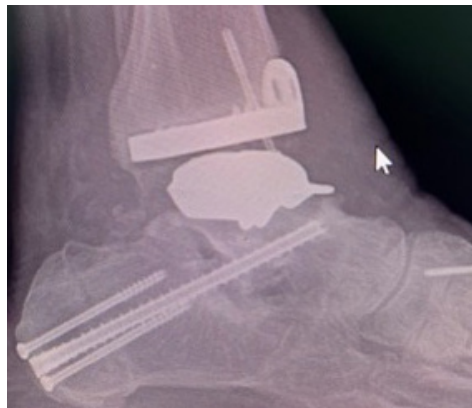Intra-op images showing placement of the definitive revision ankle implant in anatomic position.

OUTCOME

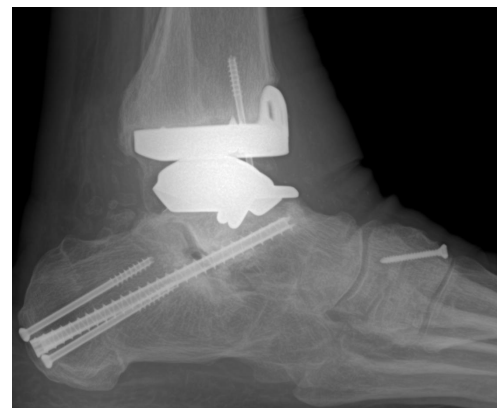After 4 weeks the patient was allowed to partially weight bear in the CAM walker. At 7 weeks post-op, the patient no longer had pain, was weight bearing, and beginning to wear regular shoe gear. At 1 year, the implant is still intact and the patient continues to be pain free.



3 months post-op: Talar component is intact without loosening or subsidence.



6 months post-op: Implant is still intact and the patient is pain free.



One year post-op: Implant is still intact and the patient continues to be pain free.



BONESUPPORT AB
Ideon Science Park,
Scheelevägen 19
SE-223 70 Lund,
Sweden

T: +46 46 286 53 70
F: +46 46 286 53 71
E: info@bonesupport.com

BONESUPPORT, INC.,
60 William St, Suite 330
Wellesley, MA 02481

T: 1.877.719.6718
E: us.sales@bonesupport.com
W: bonesupport.com

