

■ **BIOMATERIALS**

A comparison of clinical and radiological outcomes between two different biodegradable local antibiotic carriers used in the single-stage surgical management of long bone osteomyelitis



**J. Ferguson,
J. Bourget-Murray,
A. J. Hotchen,
D. Stubbs,
M. McNally**

From Nuffield
Orthopaedic Centre,
Oxford University
Hospitals NHS
Foundation Trust,
Oxford, UK

Aims

Dead-space management, following dead bone resection, is an important element of successful chronic osteomyelitis treatment. This study compared two different biodegradable antibiotic carriers used for dead-space management, and reviewed clinical and radiological outcomes. All cases underwent single-stage surgery and had a minimum one-year follow-up.

Methods

A total of 179 patients received preformed calcium sulphate pellets containing 4% tobramycin (Group OT), and 180 patients had an injectable calcium sulphate/nanocrystalline hydroxyapatite ceramic containing gentamicin (Group CG). Outcome measures were infection recurrence, wound leakage, and subsequent fracture involving the treated segment. Bone-void filling was assessed radiologically at a minimum of six months post-surgery.

Results

The median follow-up was 4.6 years (interquartile range (IQR) 3.2 to 5.4; range 1.3 to 10.5) in Group OT compared to 4.9 years (IQR 2.1 to 6.0; range 1.0 to 8.3) in Group CG. The groups had similar defect sizes following excision (both mean 10.9 cm³ (1 to 30)). Infection recurrence was higher in Group OT (20/179 (11.2%) vs 8/180 (4.4%), $p = 0.019$) than Group CG, as was early wound leakage (33/179 (18.4%) vs 18/180 (10.0%), $p = 0.024$) and subsequent fracture (11/179 (6.1%) vs 1.7% (3/180), $p = 0.032$). Group OT cases had an odds ratio 2.9-times higher of developing any one of these complications, compared to Group CG (95% confidence interval 1.74 to 4.81, $p < 0.001$). The mean bone-void healing in Group CG was better than in Group OT, in those with \geq six-month radiological follow-up (73.9% vs 40.0%, $p < 0.001$).

Conclusion

Local antibiotic carrier choice affects outcome in chronic osteomyelitis surgery. A biphasic injectable carrier with a slower dissolution time was associated with better radiological and clinical outcomes compared to a preformed calcium sulphate pellet carrier.

Cite this article: *Bone Joint Res* 2023;12(7):412–422.

Keywords: Osteomyelitis, Local antibiotics, Bone infection, Surgery, Healing

Article focus

■ To compare clinical outcomes between two different types of biodegradable local antibiotic carriers used in the single-stage treatment of chronic osteomyelitis.

■ To compare the percentage of bone-void healing seen in follow-up radiographs between the two groups.

Correspondence should be sent to Jamie Ferguson; email: jamiefergusonresearch@gmail.com

doi: 10.1302/2046-3758.127.BJR-2022-0305.R2

Bone Joint Res 2023
2023;12(7):412–422.

Key messages

- A biphasic carrier containing calcium sulphate and hydroxyapatite along with gentamicin was associated with less wound leakage, less infection recurrence, a lower fracture rate, and improved bone-void healing compared to a calcium sulphate pellet carrier containing tobramycin.
- The type of biodegradable local antibiotic carrier used seems to have an impact on the rate of complications seen in treating Cierny-Mader types III and IV chronic osteomyelitis.

Strengths and limitations

- This is a large series of cases treated for chronic osteomyelitis with prolonged clinical follow-up.
- Radiological changes may not correlate with actual bone-void healing.
- This study is subject to the limitations of being retrospective.

Introduction

The surgical treatment of chronic osteomyelitis (cOM) relies on the excision of non-viable bone, in the zone of infection. This often leaves a cavity within the bone that can act as a dead-space, which fills with haematoma, providing an ideal culture medium for residual organisms to proliferate, potentially leading to persistent infection.¹ In addition, any unhealed cavity may act as a stress riser, heightening the risk of subsequent fracture through the treated segment of bone.^{2,3} Consequently, dead-space management is an important element in cOM treatment. However, there is still considerable debate on the best method of addressing dead-spaces.

Given the growing interest in treating cOM using a single-stage protocol, antibiotics have been combined with different biodegradable carriers as a medium to fill residual dead-space and deliver high local antibiotic concentrations, reducing the risk of local recurrence without adverse systemic impacts.⁴⁻¹¹ Following antibiotic elution, they progressively dissolve, providing an osteoconductive scaffold for bone healing.¹² Two examples of such bioabsorbable antibiotic carriers include an α -hemihydrate calcium sulphate carrier containing 4% tobramycin that is available in preformed pellets (Osteoset T; Wright Medical, USA), and a biphasic carrier containing a mixture of 60% calcium sulphate, 40% hydroxyapatite with 17.5 mg/ml gentamicin, which is available as an injectable paste (Cerament G; Bonesupport AB, Sweden). While both have previously been shown to be effective in the treatment of cOM,^{13,14} comparative studies between similar groups are lacking.

Osteoset T is effective in eradicating infection in cOM, but one study reported prolonged wound ooze and unreliable bone formation, with fractures occurring in 4.6% of the treated osteomyelitic segments.¹³ However, this study included patients with Cierny-Mader (C-M)¹⁵ I and II cOM, which risks underestimating the rates of treatment failure in the more challenging cases with

C-M III and IV, since most types I and II tend to do well. The clinical outcomes following surgery for cOM using Cerament G have also been investigated.^{14,16} Radiological resolution of bone defects has recently been shown to be associated with bone formation and supported by histological analysis.¹⁶

The purpose of this study was to assess the clinical and radiological outcomes of two different biodegradable antibiotic carriers for dead-space management in patients with C-M III and IV cOM with single-stage surgery. We also quantified the percentage difference in radiological bone-void filling at final follow-up between these cohorts.

Methods

This retrospective review of a prospectively collected database of cases treated for cOM looked at two consecutive series of patients treated at a single tertiary centre with a well-established musculoskeletal infection unit. Patients from both cohorts were treated by the same multidisciplinary team, including orthopaedic and plastic surgeons specializing in bone infections, as well as microbiologists and infectious disease specialists. To facilitate comparisons between cohorts, only patients with localized (type III C-M) or diffuse (type IV C-M) cOM were included. All patients required a minimum one-year clinical follow-up and a minimum of six months' radiological follow-up to radiologically quantify differences in percentage of bone-void filling between treatment groups.

Between 2006 and 2013, patients with cOM were treated with Osteoset T (Group OT) as part of a single-stage surgery. In 2013, the unit introduced the newly licensed carrier Cerament G (Group CG), allowing a comparison to be made between the two cohorts. The treatment protocols remained the same for both cohorts over this time period. In particular, the patients were treated by the same surgeons and physicians, had the same diagnostics and definition of infection, the same antimicrobial therapy (empiric and definitive), and the same soft-tissue management and stabilization techniques. Osteoset T contains tobramycin and Cerament G contains gentamicin, two different aminoglycosides. No other changes were made to the treatment regime for the two groups, allowing a direct comparison of clinical and radiological outcomes.

Inclusion criteria. The included cases comprise a consecutive series between April 2006 and November 2017. To be eligible for inclusion, patients had to have confirmed cOM, as defined by symptoms for a minimum of six months, as well as clinical and radiological signs accompanied by at least one of the following: a draining sinus; an abscess or intraoperative pus; or two or more microbiological cultures with indistinguishable microorganisms or positive histology supportive of cOM.¹⁵ Cases with C-M type III or IV were included.

Exclusion criteria. Patients with osteomyelitis of the foot due to diabetes were excluded. Any patients with calcium metabolism disorders, renal failure, or a known allergy

to calcium sulphate, hydroxyapatite, or aminoglycosides were also excluded. Cases with C-M type I or II disease were excluded, as were any cases treated with a combination of different antibiotic carriers.

Three patients from Group OT were excluded from analysis because they died within the first year after index surgery for reasons other than infection. All these cases were infection-free when they died. There were a further four deaths in Group OT after the first year and a total of four deaths in Group CG (all occurring after the first year of treatment). None of these deaths were related to infection recurrence.

Data collection. Patient demographic details were prospectively added to a hospital infection database, which involved the contemporaneous recording of the following: surgery characteristics, infection aetiology, the presence of a sinus, microbiology and histology results, choice of antibiotic, and duration of treatment. Furthermore, any details of postoperative wound issues lasting beyond the first week were also recorded prospectively. The final clinical outcomes of infection recurrence, subsequent fracture, and radiological assessment in all patients were assessed retrospectively by reviewing follow-up clinic letters and images, and contacting patients for telephone review.

The C-M classification system was used to classify the infection for each case. This system classifies the infection based on the extent of bony involvement as well as the degree of physiological compromise in the host, taking into account both local and systemic factors.¹⁵ The extent of bony involvement was determined at the time of surgery. The host's physiological status was recorded at presentation as either Class A (no comorbidities) or Class B (compromised host).¹

Surgical management. All patients were treated in a single stage.^{13,14,17} This included excision of avascular bone and foreign material, multiple intraoperative tissue sampling, culture-specific systemic antibiotics, stabilization, dead-space filling, and primary skin closure. Antibiotic therapy was stopped at least two weeks prior to surgery, provided it was safe to do so. Multiple deep intraoperative samples were taken, using an established protocol.¹⁸⁻²⁰ Intravenous vancomycin (continued as 1 g every 12 hours) and meropenem (continued as 500 mg every eight hours) were given following sampling, as this regime was effective against 97.8% of the isolated organisms in a previous study.²¹ Meropenem was discontinued at 48 hours if no Gram-negative organisms were cultured.

Sinus tracts were excised, and any infected implants removed. Where possible, a tourniquet was used. The infected area was then fully exposed to allow careful resection of all dead bone. Excision continued until healthy, bleeding bone was exposed. After excision, the area was irrigated with 0.05% aqueous chlorhexidine solution and the cavity dried with gauze packing. The only difference in treatment protocol between cohorts was in the type of biodegradable local antibiotic carrier used to manage the remaining bone defect. No additional material or

antibiotic was added. If instability was present, stabilization was provided by external or internal fixation. Skin closure was achieved either primarily or by local or free microvascular muscle flaps at the same operation. Antibiotic treatment usually continued for six to 12 weeks based on the results of the final culture.

Outcome measures. The primary outcome measure was the rate of recurrence of infection during follow-up. This was defined as any one of the following: a) recurrent infection with positive cultures from further radiologically guided aspiration or biopsy; b) recurrent sinus formation; c) further surgery performed for infection; or d) any patient requiring long-term antibiotic treatment for persistent symptoms. Secondary outcome measures included the rate of postoperative wound leakage, the rate of subsequent fracture affecting the treated bone segment, and the percentage of bone-void filling at final follow-up, as defined on orthogonal view plain-film radiographs.

Radiological analysis. In all patients, radiographs of the operated bone were taken immediately postoperatively. Outpatient radiographs were performed at six weeks, three, six, and 12 months, and yearly thereafter. The location of the infection was classified as metaphyseal, diaphyseal, or metadiaphyseal. Orthogonal postoperative images were examined to delineate the extent of the bone-void filled with the biodegradable local antibiotic carrier. The amount of resorption or remodelling was measured by comparing the patient's initial postoperative radiographs to their latest follow-up radiographs.

SketchAndCalc Area Calculator software was used to determine the percentage of resorption or remodelling at a minimum six months' follow-up.²² This software was chosen due to its capability of accurately calculating irregular areas of uploaded digital images. Once radiographs were imported into the software, images were calibrated using the area calculators autoscale tool. The software's area calculator app and image magnification were used to freehand-draw the perimeter of the space filled by the carrier immediately after surgery (i.e. initial carrier area), and the remaining bone-void at final follow-up (i.e. residual bone-void) (Figure 1). The following formula was used to calculate the void size on each view: $(\text{initial carrier surface area} - \text{residual bone-void}) / \text{initial carrier surface area}$.

This process was done for both anteroposterior and lateral views. These two percentage scores were added together and divided by two to give the final mean percentage void-filling. The percentage of new bone occupying the space that was initially filled by the carrier was measured to the nearest 5%. This was performed for each patient. A previous study has demonstrated a Cohen's weighted Kappa score for intraobserver reliability of 0.771 (standard error 0.0386, 95% confidence interval (CI) 0.6954 to 0.8466) for this methodology, suggesting substantial agreement in measurements.¹⁶

Statistical analysis. Data were collected using an Excel spreadsheet (Microsoft, USA) and analyzed using SPSS v20 (IBM, USA). All data were considered to be

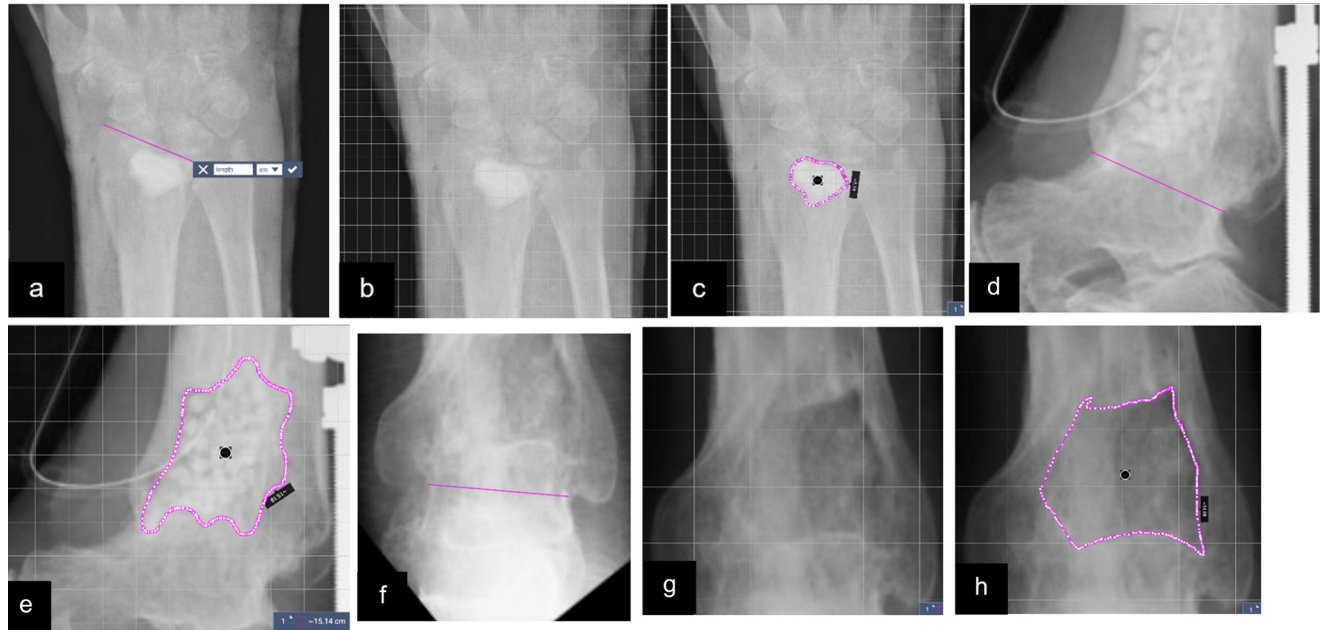


Fig. 1

Radiographs demonstrating the technique for measuring bone-void healing. Figures a) to c) show the immediate postoperative radiograph of an 85-year-old woman taken after insertion of Cerament G into a distal radial osteomyelitis void. a) A fixed landmark is measured using the SketchAndCalc Area Calculator software.²² b) A calibration scale is applied, and c) the circumference of the carrier is mapped out. This is repeated for the lateral view. Figures d) and e) show the same process for an immediate postoperative lateral radiograph in a 57-year-old man with a distal tibial osteomyelitis void above a previous ankle fusion treated with Osteoset T. Figures f) to h) demonstrate the degree of bone healing at final follow-up on the anteroposterior (AP) radiographs (one year following surgery). The degree of bone healing is calculated on both the AP and lateral views.

non-parametric. Associations between categorical variables were made using Fisher's exact test on account of low cell frequencies. Continuous variables were compared using a Mann-Whitney U test for two groups. A p-value of < 0.05 was considered to be statistically significant.

Results

A total of 359 patients were included in this study. Following osteomyelitis excision, the bone-void was filled with Osteoset T (Group OT) in 179 patients (139 males) and with Cerament G (Group CG) in 180 patients (122 males).

Group OT patients had a median age of 47.4 years (interquartile range (IQR) 34.2 to 59.2; range 16 to 82) and a median follow-up of 4.6 years (IQR 3.2 to 5.4; range 1.3 to 10.5). Group CG patients had a median age of 51.7 years (IQR 39.4 to 63.4; range 17 to 89) and median follow-up of 4.9 years (IQR 2.1 to 6.0; range 1.0 to 8.3).

Group OT included 143 patients (79.9%) with C-M III cOM and 36 patients (20.1%) with C-M IV cOM. A total of 120 patients (67.0%) were C-M class B, indicating a compromised host status.

In Group CG the distribution of C-M classification was similar (type III in 141 (78.3%) and type IV in 39 (21.7%)), although the proportion of cases with host compromise was higher, with 140 (77.8%) patients having a Class B physiological status ($p = 0.025$, Fisher's exact test). A description of the distribution of cases in each group by

C-M classification, infection location, soft-tissue cover, and skeletal stabilization is presented in Table I.

A local or free flap was required for soft-tissue cover in 24% (43/179) of cases in Group OT, compared to 30.6% (55/180) in Group CG. Osseous stabilization was required in 26.8% (48/179) of Group OT, compared to 16.7% (30/180) in Group CG. External fixation was used in all 48 Group OT cases, but in Group CG 27 had external fixation and three had internal fixation (Table I). The median bone defect volume was the same between the two groups (both = 10 cm^3 (IQR 6 to 15)).

The aetiology of infection was similar across both groups, with infection following fracture fixation being 60.3% in Group OT and 63.3% in Group CG. The most common causative organism in both groups was methicillin-susceptible *Staphylococcus aureus* (MSSA) accounting for 25% of all cases. Polymicrobial infection was seen in 20.3% of cases (Table II).

Outcome measures: recurrence of infection. In Group OT there was a higher infection recurrence rate during follow-up (20/179 (11.2%) vs 8/180 (4.4%)) in Group CG ($p = 0.019$, Fisher's exact test). The median time to infection recurrence in Group OT was 6.7 months (IQR 4.8 to 20.8; range 1.0 to 65.3) (Figure 2). Overall, 13 cases (65%) were successfully treated with an additional operation. A further five cases were treated with prolonged antibiotics alone, with three having no recurrence after stopping antibiotics and two having an ongoing discharging sinus. The other two cases, both treated for

Table 1. Patient details for each group organized by bone affected, Cierny-Mader classification, soft-tissue cover, and requirement for osseous stabilization during the single-stage surgery.

Group	OT	n	Cierny and Mader Stage										Soft-tissue cover				Fixation		
			III A	III B ^L	III B ^S	III B ^{LS}	IV A	IV B ^L	IV B ^S	IV B ^{LS}	Direct closure	Local flap	Free flap	None	External fixation	Internal fixation			
Bone	Tibia	81	20	29	11	11	1	6	3	44	9	28	58	3	20	Ilizarov			
	Femur	63	17	17	8	7	4	3	3	61	2		50	10	3	Ilizarov			
	Humerus	9	3	2	2	2	2	2	8	1		8	1	1	Mono				
	Forearm	6	3	2	2	1	1	1	6			4	1	1	Mono, 1 Ilizarov				
	Foot	4	1	1	2	2	1	1	4			4							
	Pelvis	4	1	2	2	1	1	1	3	1		4							
	Knee	4	1	1	1	1	1	1	4			2		2	Ilizarov				
	Ankle	8	1	1	1	4	2	2	6		2	1		7	Ilizarov				
Total		179	46	53	23	21	13	12	4	7	136	13	30	48					
Group CG																			
Bone	Tibia	84	10	28	5	26	4	3	4	41	11	32	69	15	(11 Iliz, 4 mono)				
	Femur	38	12	7	5	7	2	1	4	36	1	1	30	7	Mono				
	Humerus	20	4	2	6	1	1	1	4	19	1		16	2	Mono				
	Forearm	14	6	5	5	1	1	1	1	14			13	1	Mono				
	Foot	7	1	3	1	2	2	2	6		1	7							
	Clavicle	2		2	2				2			2	2						
	Pelvis	2		2	2				2			2	2						
	Shoulder	4	1		1	1	2	2	2	2	2	3		1	Ilizarov				
	Knee	1						1	1	1				1	Ilizarov				
	Ankle	8	3	3	1	1	1	1	3	2	6	4		4	Ilizarov				
Total		180	34	43	26	38	6	7	10	125	15	40	146	31					

A = normal host; B^L = host with local compromise; B^S = host with systemic compromise; B^{LS} = host with local and systemic compromise. CG, Cerament G; IMN, intramedullary nail; Mono, monolateral external fixator; OT, Osteoset T.

Table II. The aetiology and microbiology of the two groups in this study.

Group OT	n	Aetiology			
		Post-fracture	Haematogenous	Post-elective surgery	Soft-tissue
Microbiology					
Polymicrobial	39	24	5	6	4
No growth	44	23	15	5	1
Monomicrobial					
MSSA	45	25	18	1	1
MRSA	7	6		1	
Coagulase-negative staphylococci	16	9	1	6	
<i>Pseudomonas</i>	9	7	2		
<i>Escherichia coli</i>	4	3	1		
<i>Enterobacter cloacae</i>	3	2		1	
Diphtheroids	2	2			
<i>Enterococcus</i>	2	2			
<i>Proteus</i>	2	1		1	
<i>Candida</i>	2	2			
<i>Klebsiella</i>	1		1		
<i>Bacteroides</i>	1	1			
<i>Mycobacterium</i>	2	1	1		
Total	179	108	44	21	6
Group CG					
Polymicrobial	34	23	5	4	2
No growth	62	40	17	4	1
Monomicrobial					
MSSA	45	23	12	9	1
MRSA	5	4	1		
Coagulase-negative staphylococci	5	4	1		
<i>Pseudomonas</i>	7	5		2	
<i>Enterobacter cloacae</i>	5	4		1	
<i>Corynebacterium</i>	3	2		1	
<i>Serratia</i>	3	3			
<i>Streptococcus spp.</i>	2	2			
<i>Achromobacter</i>	2	1			1
<i>Bacillus</i>	2	1		1	
<i>Salmonella</i>	1		1		
<i>Proteus</i>	1	1			
<i>Cutibacterium acnes</i>	1		1		
<i>Clostridium difficile</i>	1	1			
<i>Mycobacterium</i>	1		1		
Total	180	114	39	22	5

Soft-tissue relates to any infection caused primarily by soft-tissue damage, e.g. pressure ulceration or burns.

CG, Cerament G; MRSA, methicillin-resistant *Staphylococcus aureus*; MSSA, methicillin-susceptible *Staphylococcus aureus*; OT, Osteoset T.

polymicrobial infections complicating arthrodesis of the knee, failed to respond to further surgery and both opted for an above-knee amputation, which eradicated their infection.

The median time to infection recurrence in Group CG was 7.6 months (IQR 6.3 to 17.7; range 2.3 to 25.0). Seven cases were successfully treated with an additional operation. The other case underwent revision surgery for calcaneal osteomyelitis; nine months following revision, he developed discharge from the wound. This subsequently resolved without intervention and the patient remains symptom-free three years following his revision surgery.

Outcome measures: leakage of the implanted material from the wound. The rate of early wound leakage following surgery was higher in Group OT (33/179 (18.4%)) compared to 18/180 (10.0%) in Group CG ($p = 0.024$, Fisher's exact test). In Group OT, 27/33 of these cases required no intervention for their wound ooze, which eventually settled. In 6/33 cases (18.2%) with early wound leakage, there was subsequently a recurrent infection.

In Group CG, only one of the 18 cases with wound leakage had a recurrent infection (5.6%). The remaining 17 cases all resolved without any intervention. Early wound leakage was not associated with a higher rate of later infection recurrence in either group, compared

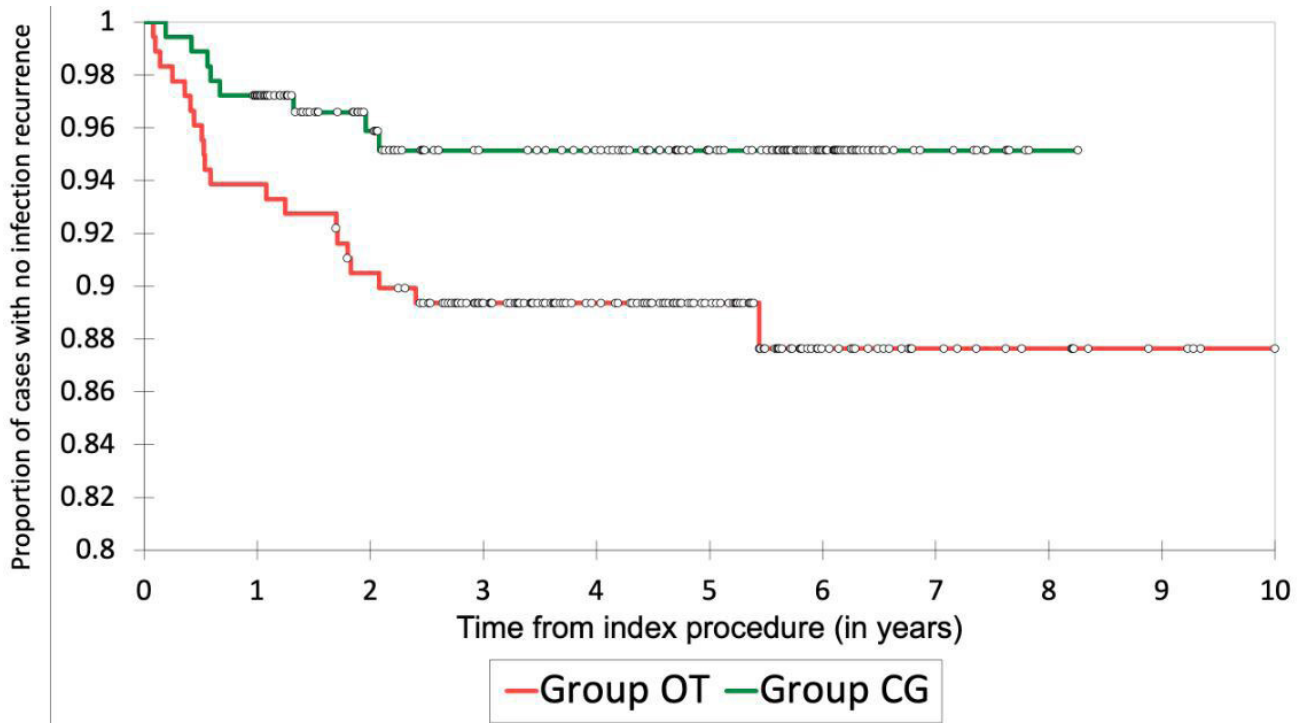


Fig. 2

Kaplan-Meier curve demonstrating infection recurrence over time in Group OT (Osteoset T) and Group CG (Cerament G). Censored data are marked with circles.

to cases with no wound leakage beyond the first week following surgery.

Outcome measures: fracture. The rate of subsequent fracture involving the treated segment was higher in Group OT at 6.1% (11/179) vs 1.7% (3/180) in Group CG, ($p = 0.032$, Fisher's exact test). In Group OT, the median time to fracture was 1.4 years following index procedure (IQR 7.0 to 41.0; 1 week to 7.6 years), with 7/11 of the fractures occurring more than one year after surgery. All of the fractures in Group OT occurred in the lower limb (seven in the femur and four in the tibia). Eight out of the 11 cases were treated with an external fixator at time of index surgery, to either protect the resection segment from fracture or secure union. Of these 11 cases who sustained fracture, 7/11 underwent revision surgery to stabilize the fracture (four requiring an external fixator, three requiring plating). The remaining four cases were treated with casting.

Three cases in Group CG sustained a fracture between one and 11 months following surgery. One of these cases occurred 11 months following excision of tibia osteomyelitis treated with a flap, and three months in an Ilizarov frame at index surgery. The other two were in the humerus and radius (both occurring one month following index surgery), which were not treated with fixation at time of index procedure. There were no late fractures seen beyond the first year following surgery. The tibia and humerus fractures were treated with casting and went on to heal uneventfully. The radius was initially

splinted in view of the patient's medical comorbidities. This did not secure union, but the patient declined revision fixation due to her lack of ongoing symptoms.

Patients in Group OT had an odds ratio 2.7-times higher of developing recurrent infection (95% confidence interval (CI) 1.16 to 6.31, $p = 0.021$), 2.03-times higher of developing wound leakage (95% CI 1.10 to 3.77, $p = 0.024$), and 3.86-times higher of developing a subsequent fracture in the treated segment (95% CI 1.06 to 14.09, $p = 0.041$) compared to Group CG. The overall risk of developing any one of these complications in Group OT was 2.9-times higher compared to patients in Group CG (95% CI 1.74 to 4.81, $p < 0.001$).

Radiological analysis. There were 137 cases in Group OT (median follow-up 1.4 years (IQR 0.8 to 3.2, range 0.5 to 10.5)), with a minimum of six months' radiological follow-up and 166 cases (median follow-up 1.3 years (IQR 1.0 to 2.0, range 0.5 to 4.8)) in Group CG. In these cases, the mean bone-void healing in Group CG was significantly better than in Group OT (73.9% vs 40.0%, $p < 0.001$, Mann-Whitney U test (median 80% (IQR 60% to 90%) vs 40% (IQR 0% to 70%))) (Figure 3).

In Group OT, there was no difference in the mean bone healing seen in the metaphysis (41.6%) versus the diaphysis (37.7%). However, in Group CG there was a difference in mean bone healing between the metaphysis (78.4% (median 80%, IQR 70% to 95%)) and the diaphysis (66.9% (median 80%, IQR 50% to 90%)) ($p = 0.030$, Mann Whitney U test).

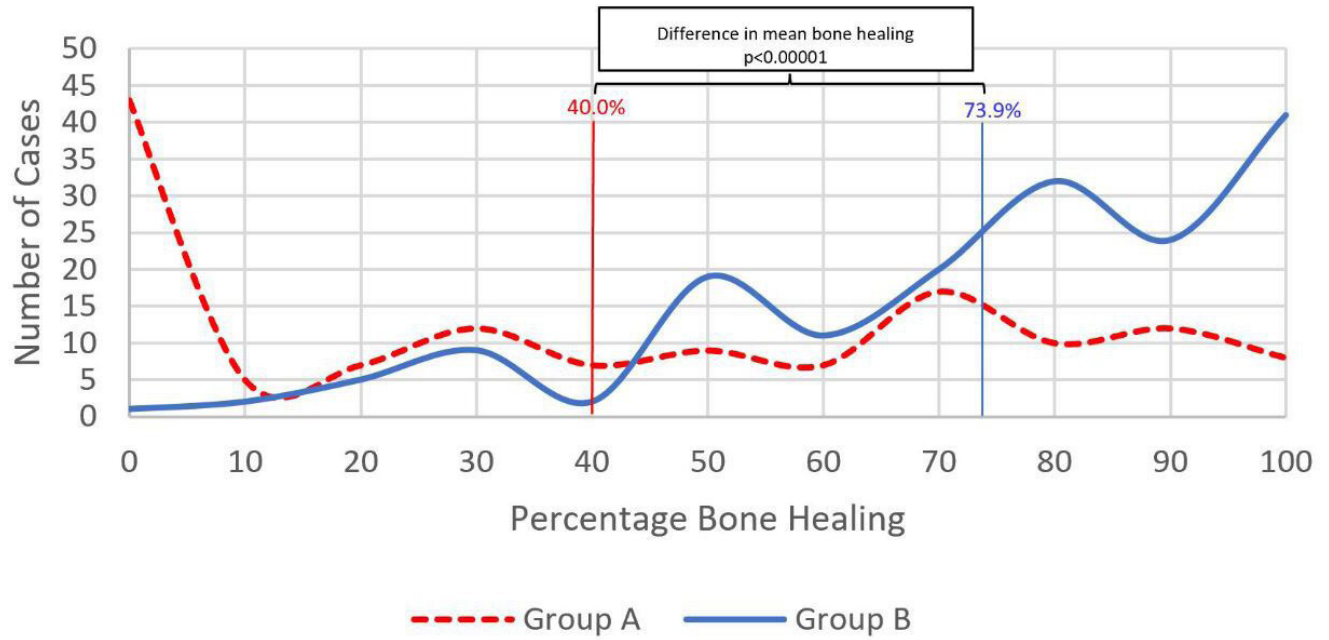


Fig. 3

The percentage bone-void filling seen at final follow-up in the two groups. The percentages represent the mean in the two groups.

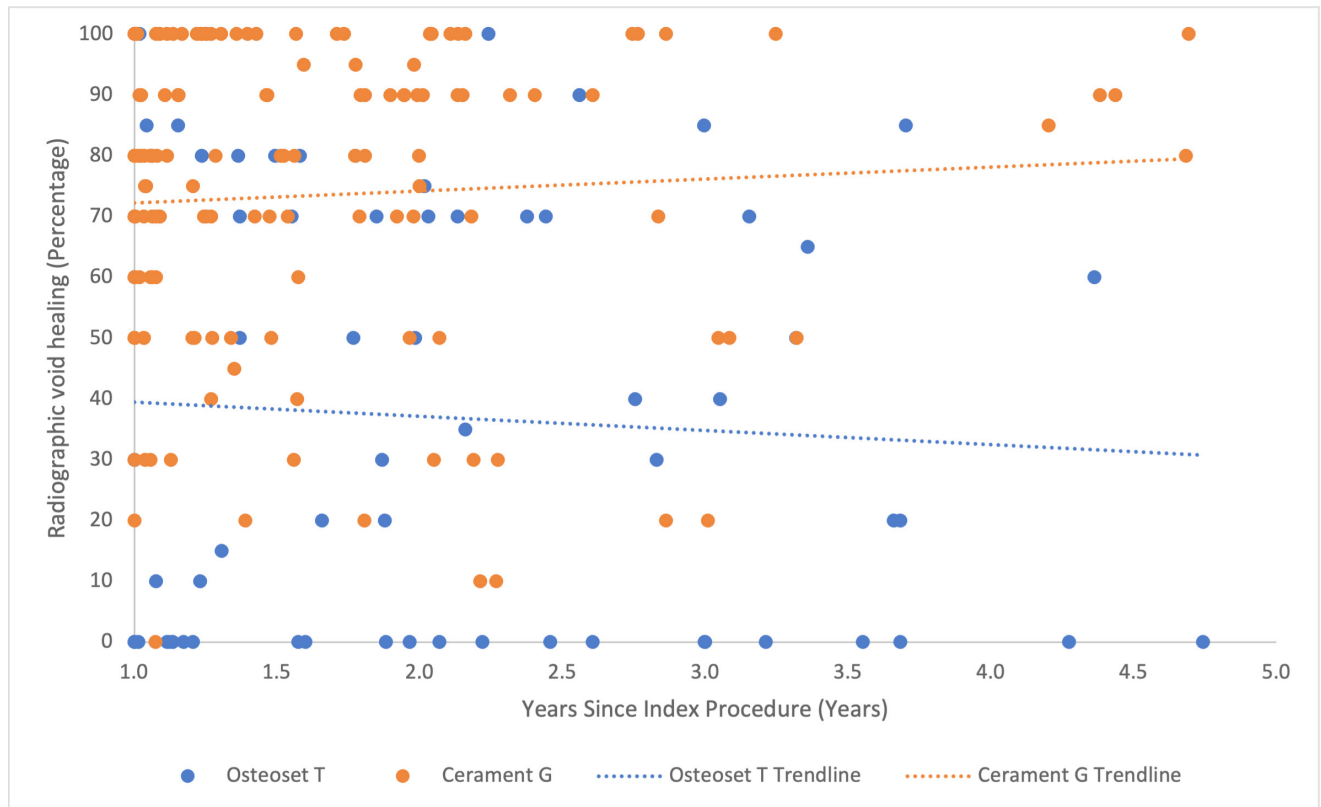


Fig. 4

Scatter plot of percentage radiological bone healing at final follow-up against time after index infection surgery.

A further analysis of the bone-void healing studied a subgroup with a minimum one-year follow-up and a maximum five-year follow-up, to allow a clearer comparison across the two groups and define the effect of time of bone formation (Figure 4). This subgroup contained 69 Osteoset T cases and 145 Cerament G cases. The minimum 12-month follow-up was selected to minimize the risk of falsely attributing bone healing to residual carrier material in the first year. After adjusting for time following surgery, there remained a significant difference in bone void healing between the groups on multivariate linear regression analysis ($p < 0.001$).

Discussion

Historically, local antibiotics have been added to polymethyl methacrylate (PMMA) to manage bone infection.^{23–27} However, the disadvantages of this technique include the potential for thermal necrosis caused by cement curing, the potential for antibiotic resistance due to low-level elution of antibiotics from the spacer over a long time, and the lack of spontaneous bone repair without spacer removal.

The use of bioabsorbable local antibiotic in the management of dead-space has many advantages over traditional staged procedures for managing infection. By achieving definitive soft-tissue closure there is less chance of translocation of organisms into the wound, which minimizes the selection of resistant organisms. There is no need for additional surgery to remove any foreign material or undertake later bone grafting, and the patient can recover faster. In this series, no patient required subsequent bone grafting.

Local antibiotics can be administered in high concentrations with little systemic toxicity, avoiding adverse antibiotic reactions and removing concerns with compliance. While systemic antibiotics are routinely administered following surgery, to target any residual organisms, the perfusion into treated bone defects might be suboptimal, resulting in low antibiotic penetration.²⁸ Unlike systemic antibiotics, local antibiotics are not reliant on the often-compromised perfusion present at the site of infection to achieve antibiotic delivery. Insertion of antibiotic directly at the site of infection achieves a concentration many times greater than would otherwise be achieved by systemic therapy, while minimizing systemic toxicity.^{4,11} This has the additional benefit of impeding biofilm formation on devascularized bone. An animal model has demonstrated that local delivery of antibiotics into a bone defect is superior to systemic antibiotics alone at 14 days following surgery.²⁹

The current study demonstrates that single-stage osteomyelitis surgery, in combination with dissolving local antibiotic carriers, achieved clinical infection clearance rates of 88.8% and 95.6% in the two groups at a median follow-up time of 4.6 and 4.9 years, respectively. These outcomes are delivered in the context of a multidisciplinary team environment specializing in the management of bone infection. Delivering care for

musculoskeletal infection within a dedicated multidisciplinary team has been shown to lead to improved outcomes.^{30,31}

However, the choice of local antibiotic carrier had a significant impact on clinical outcome. The rate of infection recurrence and other complications was lower in those treated with Cerament G, as opposed to Osteoset T. This is despite there being a higher rate of associated host compromise in this group, which is traditionally associated with worse outcomes.^{15,32,33} Although Osteoset T contains tobramycin and Cerament G contains gentamicin, both these antibiotics are aminoglycosides with very similar spectrums of activity.³⁴

Other studies have demonstrated significant ongoing fracture rates following osteomyelitis treatment, ranging from 5.5% to 8.0%.^{2,35,36} A fracture involving a previously treated osteomyelitis segment may not be an entirely benign problem to address. In Group OT, two-thirds of cases with a fracture required surgical fixation. The fracture rate in Group CG was low. Interestingly, most of the fractures seen in Group OT occurred late, at a mean of 2.3 years following surgery, with 63.6% occurring after the first year. In Group CG, all fractures occurred within the first 11 months. This suggests that there is ongoing remodelling of the carrier with bone maturation, which may prevent the delayed fracture risk seen with the use of calcium sulphate carriers. Calcium sulphate dissolution is rapid and may be too quick to allow reproducible bone formation.¹² Osteoset T has been observed to resorb at a mean of 2.7 months from insertion.²

In Cerament G, the dissolution of calcium sulphate leaves behind a complex hydroxyapatite scaffold which allows bone deposition over a prolonged period.³⁷ In another study, bone remodelling beyond the second year following surgery was seen in 63% of radiographs.¹⁶

It is unclear to what extent the form of the carrier impacts the difference in clinical outcomes. In a previous study, it was shown that there is improved bone formation when Cerament G has good initial contact with the bone cavity.¹⁶ Cerament G may be able to achieve better bone contact because it can be injected into cavities and coat the surface of the endosteum, unlike the pre-made Osteoset T pellets. It is not clear to what degree the contrasting physical properties of the two materials (one as pellets and the other as an injectable paste) may explain the difference in clinical outcomes between the two groups.

The limitations of this study relate to its retrospective nature. Unfortunately, not every patient had radiographs beyond six months following surgery, which meant that void-filling could only be judged on last follow-up radiographs in 137/179 (76.5%) of Group OT and 166/180 (92.2%) of Group CG. This evaluation demonstrated radiological changes in the bone-void over time, but this may not fully correlate with actual bone formation. The persistence of hydroxyapatite, as the Cerament G degrades, may interfere with the radiological interpretation of bone formation. However, previous studies have

demonstrated histological evidence of bone formation by biopsies taken from treated sites in both animal and human studies, correlated with radiological appearances on plain radiographs and micro-CT.^{16,38,39}

The findings of this study have resulted in our unit reserving antibiotic carriers containing calcium sulphate alone for use in contained intramedullary bone defects (C-M Type 1), and preferring Cerament G for corticomedullary defects to support better bone formation and minimize future fracture risk.

In conclusion, the choice of local antibiotic carrier has a significant impact on outcome in the surgical treatment of chronic osteomyelitis. A biphasic carrier with a slower dissolution time in the form of an injectable paste was associated with better bone healing, reduced infection recurrence, and fewer wound leakages and fractures, compared to a preformed calcium sulphate pellet carrier.

References

- Cierny G, Mader JT, Penninck JJ. A clinical staging system for adult osteomyelitis. *Clin Orthop Relat Res.* 2003;414:7–24.
- McKee MD, Wild LM, Schemitsch EH, Waddell JP. The use of an antibiotic-impregnated, osteoconductive, bioabsorbable bone substitute in the treatment of infected long bone defects: early results of a prospective trial. *J Orthop Trauma.* 2002;16(9):622–627.
- McNally M, Nagarajah K. Mini-Symposium: Pathology (iv) Osteomyelitis. *Orthop Trauma.* 2010;24(6):416–429.
- Stravinskas M, Horstmann P, Ferguson J, et al. Pharmacokinetics of gentamicin eluted from a regenerating bone graft substitute: In vitro and clinical release studies. *Bone Joint Res.* 2016;5(9):427–435.
- Drampalos E, Mohammad HR, Kosmidis C, Balal M, Wong J, Pillai A. Single stage treatment of diabetic calcaneal osteomyelitis with an absorbable gentamicin-loaded calcium sulphate/hydroxyapatite biocomposite: The Silo technique. *Foot (Edinb).* 2018;34:40–44.
- Pincher B, Fenton C, Jeyapalan R, Barlow G, Sharma HK. A systematic review of the single-stage treatment of chronic osteomyelitis. *J Orthop Surg Res.* 2019;14(1):393.
- Lam A, Richardson SS, Buksbaum J, et al. Chronic osteomyelitis of the tibia and ankle treated with limb salvage reconstruction. *J Bone Jt Infect.* 2019;4(6):306–313.
- Lorentzen AK, Engel L, Gottlieb H, Obinah MPB. One-stage treatment of chronic osteomyelitis with an antibiotic-loaded biocomposite and a local or free flap. *Eur J Plast Surg.* 2021;44(3):367–374.
- Jiang N, Zhao X-Q, Wang L, Lin Q-R, Hu Y-J, Yu B. Single-stage debridement with implantation of antibiotic-loaded calcium sulphate in 34 cases of localized calcaneal osteomyelitis. *Acta Orthop.* 2020;91(3):353–359.
- Pesch S, Hanschen M, Greve F, et al. Treatment of fracture-related infection of the lower extremity with antibiotic-eluting ceramic bone substitutes: case series of 35 patients and literature review. *Infection.* 2020;48(3):333–344.
- Muir R, Birnie C, Hyder-Wilson R, Ferguson J, McNally MA. Does local implantation of gentamicin impair renal function in patients undergoing surgery for chronic bone infection? *Int J Res Orthop.* 2021;7(3):438.
- Ferguson J, Diefenbeck M, McNally M. Ceramic biocomposites as biodegradable antibiotic carriers in the treatment of bone infections. *J Bone Jt Infect.* 2017;2(1):38–51.
- Ferguson JY, Dudareva M, Riley ND, Stubbs D, Atkins BL, McNally MA. The use of a biodegradable antibiotic-loaded calcium sulphate carrier containing tobramycin for the treatment of chronic osteomyelitis: a series of 195 cases. *Bone Joint J.* 2014;96-B(6):829–836.
- McNally MA, Ferguson JY, Lau ACK, et al. Single-stage treatment of chronic osteomyelitis with a new absorbable, gentamicin-loaded, calcium sulphate/hydroxyapatite biocomposite: a prospective series of 100 cases. *Bone Joint J.* 2016;98-B(9):1289–1296.
- Cierny G, Mader JT, Penninck JJ. A clinical staging system for adult osteomyelitis. *Clin Orthop Relat Res.* 2003;414(414):7–24.
- Ferguson J, Athanasou N, Diefenbeck M, McNally M. Radiographic and histological analysis of a synthetic bone graft substitute eluting gentamicin in the treatment of chronic osteomyelitis. *J Bone Jt Infect.* 2019;4(2):76–84.
- McNally MA. Osteomyelitis. In: Chen A, ed. *Management of Orthopaedic Infections: A Practical Guide.* 5. Thieme, 2021: 61–87.
- Spangehl MJ, Masri BA, O'Connell JX, Duncan CP. Prospective analysis of preoperative and intraoperative investigations for the diagnosis of infection at the sites of two hundred and two revision total hip arthroplasties. *J Bone Joint Surg Am.* 1999;81-A(5):672–683.
- Atkins BL, Athanasou N, Deeks JJ, et al. Prospective evaluation of criteria for microbiological diagnosis of prosthetic-joint infection at revision arthroplasty. The OSIRIS Collaborative Study Group. *J Clin Microbiol.* 1998;36(10):2932–2939.
- Sheehy SH, Atkins BA, Bejon P, et al. The microbiology of chronic osteomyelitis: prevalence of resistance to common empirical anti-microbial regimens. *J Infect.* 2010;60(5):338–343.
- Dudareva M, Hotchen AJ, Ferguson J, et al. The microbiology of chronic osteomyelitis: Changes over ten years. *J Infect.* 2019;79(3):189–198.
- No authors listed. Area Calculator. Sketch and Calc. <https://www.sketchandcalc.com> (date last accessed 26 April 2023).
- Buchholz HW, Engelbrecht H. (Depot effects of various antibiotics mixed with Palacos resins). *Chirurg.* 1970;41(11):511–515. (Article in German).
- Wahlig H, Dingeldein E, Bergmann R, Reuss K. The release of gentamicin from polymethylmethacrylate beads. *J Bone Joint Surg Br.* 1978;60-B:270–275.
- Walenkamp GH, Vree TB, van Rens TJ. Gentamicin-PMMA beads. Pharmacokinetic and nephrotoxicological study. *Clin Orthop Relat Res.* 1986;205(205):171–183.
- Walenkamp G. Chronic osteomyelitis. *Acta Orthop Scand.* 1997;68(5):497–506.
- Tiemann AH, Schmidt HGK, Braunschweig R, Hofmann GO. Strategies for the analysis of osteitic bone defects at the diaphysis of long bones. *Strategies Trauma Limb Reconstr.* 2009;4(1):13–18.
- Öbrink-Hansen K, Pham AD, Bue M, et al. Population pharmacokinetics of flucloxacillin in bone and soft tissue - standard dosing is not sufficient to achieve therapeutic concentrations. *Pharm Res.* 2022;39(7):1633–1643.
- Rand BCC, Penn-Barwell JG, Wenke JC. Combined local and systemic antibiotic delivery improves eradication of wound contamination: An animal experimental model of contaminated fracture. *Bone Joint J.* 2015;97-B(10):1423–1427.
- Walter N, Rupp M, Baertl S, Alt V. The role of multidisciplinary teams in musculoskeletal infection. *Bone Joint Res.* 2022;11(1):6–7.
- McNally MA, Ferguson JY, Scarborough M, Ramsden A, Stubbs DA, Atkins BL. Mid- to long-term results of single-stage surgery for patients with chronic osteomyelitis using a bioabsorbable gentamicin-loaded ceramic carrier. *Bone Joint J.* 2022;104-B(9):1095–1100.
- Zimmerli W, Sendi P. Pathogenesis of implant-associated infection: the role of the host. *Semin Immunopathol.* 2011;33(3):295–306.
- Lew DP, Waldvogel FA. Osteomyelitis. *Lancet.* 2004;364(9431):369–379.
- Krause KM, Serio AW, Kane TR, Connolly LE. Aminoglycosides: An overview. *Cold Spring Harb Perspect Med.* 2016;6(6):a027029.
- Gitelis S, Brebach GT. The treatment of chronic osteomyelitis with a biodegradable antibiotic-impregnated implant. *J Orthop Surg (Hong Kong).* 2002;10(1):53–60.
- McKee MD, Li-Bland EA, Wild LM, Schemitsch EH. A prospective, randomized clinical trial comparing an antibiotic-impregnated bioabsorbable bone substitute with standard antibiotic-impregnated cement beads in the treatment of chronic osteomyelitis and infected nonunion. *J Orthop Trauma.* 2010;24(8):483–490.
- Nilsson M, Wang JS, Wielanek L, Tanner KE, Lidgren L. Biodegradation and biocompatibility of a calcium sulphate-hydroxyapatite bone substitute. *J Bone Joint Surg Br.* 2004;86-B(1):120–125.
- Dvorzhinskiy A, Perino G, Chojnowski R, van der Meulen MCH, Bostrom MPG, Yang X. Ceramic composite with gentamicin decreases persistent infection and increases bone formation in a rat model of debrided osteomyelitis. *J Bone Jt Infect.* 2021;6(7):283–293.
- Hettwer W, Horstmann PF, Bischoff S, et al. Establishment and effects of allograft and synthetic bone graft substitute treatment of a critical size metaphyseal bone defect model in the sheep femur. *APMIS.* 2019;127(2):53–63.

Author information:

- J. Ferguson, MB ChB (Hons), MEd. (Merit), FRCS (Tr & Orth), Consultant in Limb Reconstruction
- J. Bourget-Murray, MD, CM, FRCSC, Orthopaedic Fellow
- A. J. Hotchen, MBChB, PhD, Registrar in Trauma and Orthopaedics
- D. Stubbs, FRCS (Ortho), Consultant in Limb Reconstruction
- M. McNally, MD, FRCSEd, FRCS (Ortho), Consultant in Limb Reconstruction

Bone Infection Unit, Nuffield Orthopaedic Centre, Oxford University Hospitals NHS Foundation Trust, Oxford, UK.

Author contributions:

- J. Ferguson: Conceptualization, Data curation, Formal analysis, Investigation, Methodology, Project administration, Supervision, Validation, Writing – original draft, Writing – review & editing.
- J. Bourget-Murray: Formal analysis, Writing – original draft, Writing – review & editing.
- D. Stubbs: Conceptualization, Formal analysis, Investigation, Supervision, Writing – review & editing.
- M. McNally: Conceptualization, Data curation, Formal analysis, Investigation, Methodology, Project administration, Supervision, Validation, Writing – review & editing.
- A. J. Hotchen: Formal analysis.
- J. Bourget-Murray and J. Ferguson are joint first authors.

Funding statement:

- The authors received no financial or material support for the research, authorship, and/or publication of this article.

ICMJE COI statement:

- J. Ferguson reports consulting fees and payment for educational talks and presentations from BoneSupport AB, and support for being a faculty speaker at the 2022 European Bone and Joint Infection Society (EBJIS) conference, all of which are unrelated to this study. M. McNally reports textbook royalties from Oxford University Press, consulting fees and speaker payments or honoraria from BoneSupport AB,

and support for attending EBJIS and AO Foundation meetings, all of which are unrelated to this study. M. McNally also holds a leadership or fiduciary role on EBJIS and European Federation of Orthopaedics and Traumatology (EFORT). D. Stubbs reports an honorarium from Bone Support Ltd for presenting at the 2022 Welsh infection group meeting.

Data sharing:

- The data that support the findings for this study are available to other researchers from the corresponding author upon reasonable request.

Acknowledgements:

- We would like to thank the staff of the Oxford Bone Infection Unit for their commitment to the care of the patients in this study and to all our infection patients.

Ethical review statement:

- This paper had institutional ethical approval (Oxford University Hospitals, number 22/8356).

Open access funding:

- The open access fee for this study was self-funded through Oxford Bone Infection Consultancy Ltd.

© 2023 Author(s) et al. **Open Access** This article is distributed under the terms of the Creative Commons Attribution No Derivatives (CC BY-ND 4.0) licence (<https://creativecommons.org/licenses/by-nd/4.0/>), which permits the reuse of the work for any purpose, including commercially, provided the original author and source are credited; however, it cannot be distributed to others in any adapted form.