

CERAMENT[®] G
with Gentamicin

PUBLICATION SUMMARY

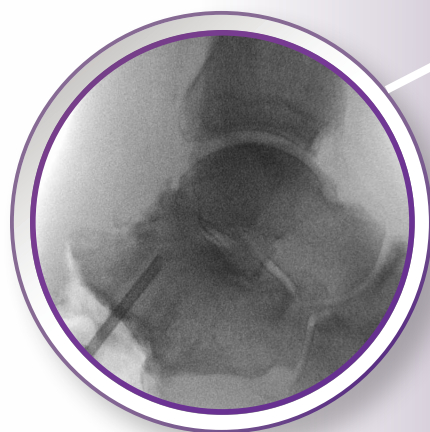
Medical Education Series

Single-Stage Treatment of Diabetic Calcaneal Osteomyelitis: The Silo Technique

CASE SERIES OF 12 PATIENTS

E. Drampalos et. al

*Trauma and Orthopaedics Department,
Wythenshawe Hospital
Manchester, United Kingdom*



Single-Stage Treatment of Diabetic Calcaneal Osteomyelitis: The Silo Technique

INTRODUCTION

The following is a summary of a publication on CERAMENT® G: Single stage treatment of diabetic calcaneal osteomyelitis with an absorbable gentamicin-loaded calcium sulphate/hydroxyapatite biocomposite: The Silo technique, as published in *The Foot* (Edinb). 2018 Mar;34:40-44..

CERAMENT® G is a new pathway to better manage osteomyelitis:

- Proven bone remodeling
- Reliable & safe local antibiotic elution
- Supports a single-stage treatment pathway

METHODS

12 consecutive diabetic patients presenting with heel ulcers and calcaneal osteomyelitis were treated by the Silo method.

The Silo method involves the debridement of dead bone and the local delivery of antibiotic in drilled tunnels using CERAMENT® G. This method is also combined with multiple sampling and culture-specific systemic antibiotic treatment guided by a multidisciplinary team.

PATIENT EXPERIENCE

A consecutive series of 12 patients diagnosed with heel ulcers and calcaneal osteomyelitis. Patients were treated by the Silo technique.

Patient demographics:

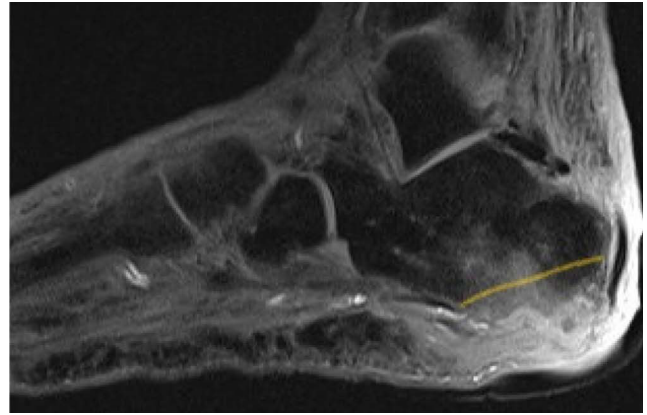
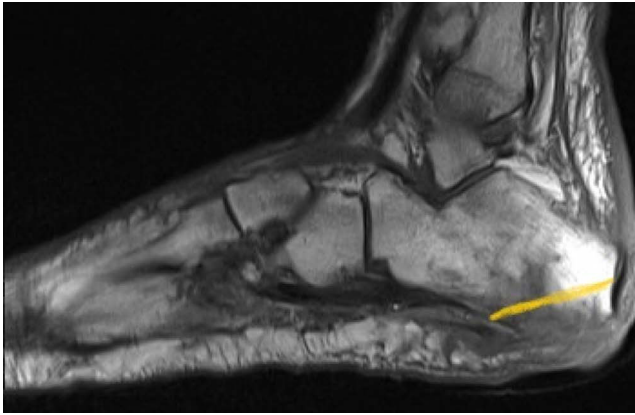
- 12 patients
- Mean age 68 years (50-85 years)
- 8 male / 4 female
- Mean follow-up 16 weeks (range 12-18)
- All 12 patients had comorbidities and were classified as Cierny-Mader class B (local and systemic compromise)

RESULTS

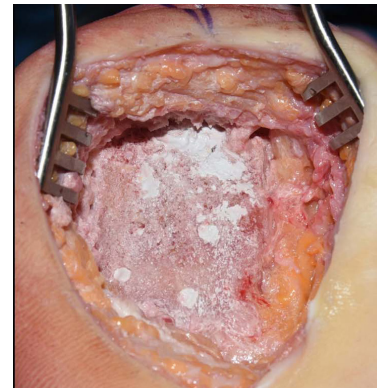
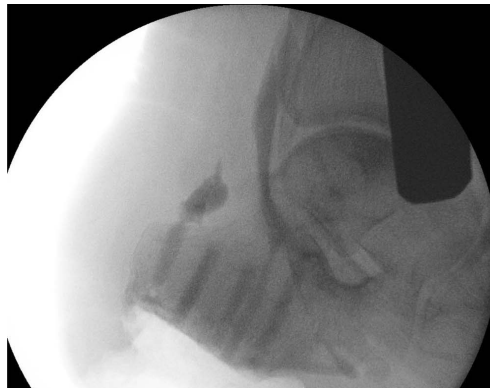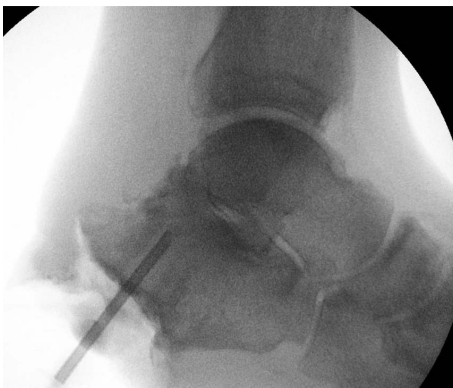
- Infection was eradicated in 12 (100%) patients with a single-stage procedure.
- Follow-up was until clinical cure of the ulcer for a mean of 16 weeks (range 12-18)
- 1 patient required a subsequent flap operation and six vacuum-assisted closures (V.A.C.)
- 1 patient had prolonged leakage
- There were no calcaneal fractures

CONCLUSIONS

Using the Silo technique along with CERAMENT® G for the local delivery of antibiotics can be effectively implemented into the single-stage treatment of calcaneal osteomyelitis. This offers increased bone preservation and local delivery of antibiotic, decreasing the need for major amputation.

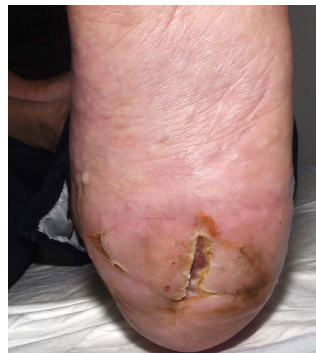
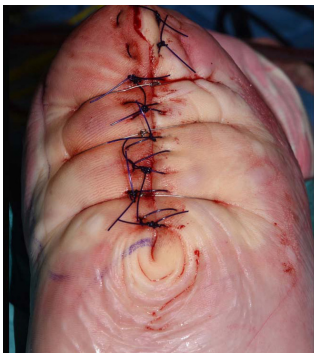
Calcaneal osteomyelitis on sagittal T1 waited (a) and T-weighted (b) MRI sections with the planned resection level, highlighted by the yellow line.



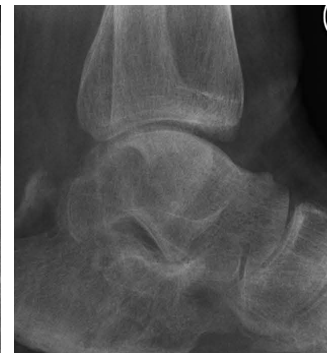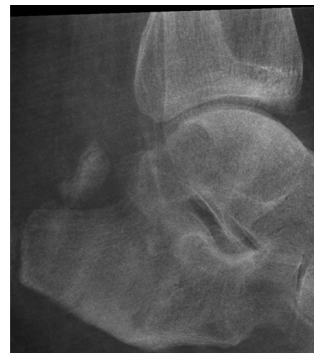Silo type tunnels (4-5) are drilled into the os calcis towards the posterior subtalar joint using a 3.2mm drill bit and least 0.5cm short of full length.

The dry Silo tunnels are filled with 5ml of radiopaque CERAEMENT® G



The wound can be closed primarily in some cases

Wound healed after primary closure



Silo tunnels before (a) and after (b) resorption of CERAEMENT® G

MICROBIOLOGY

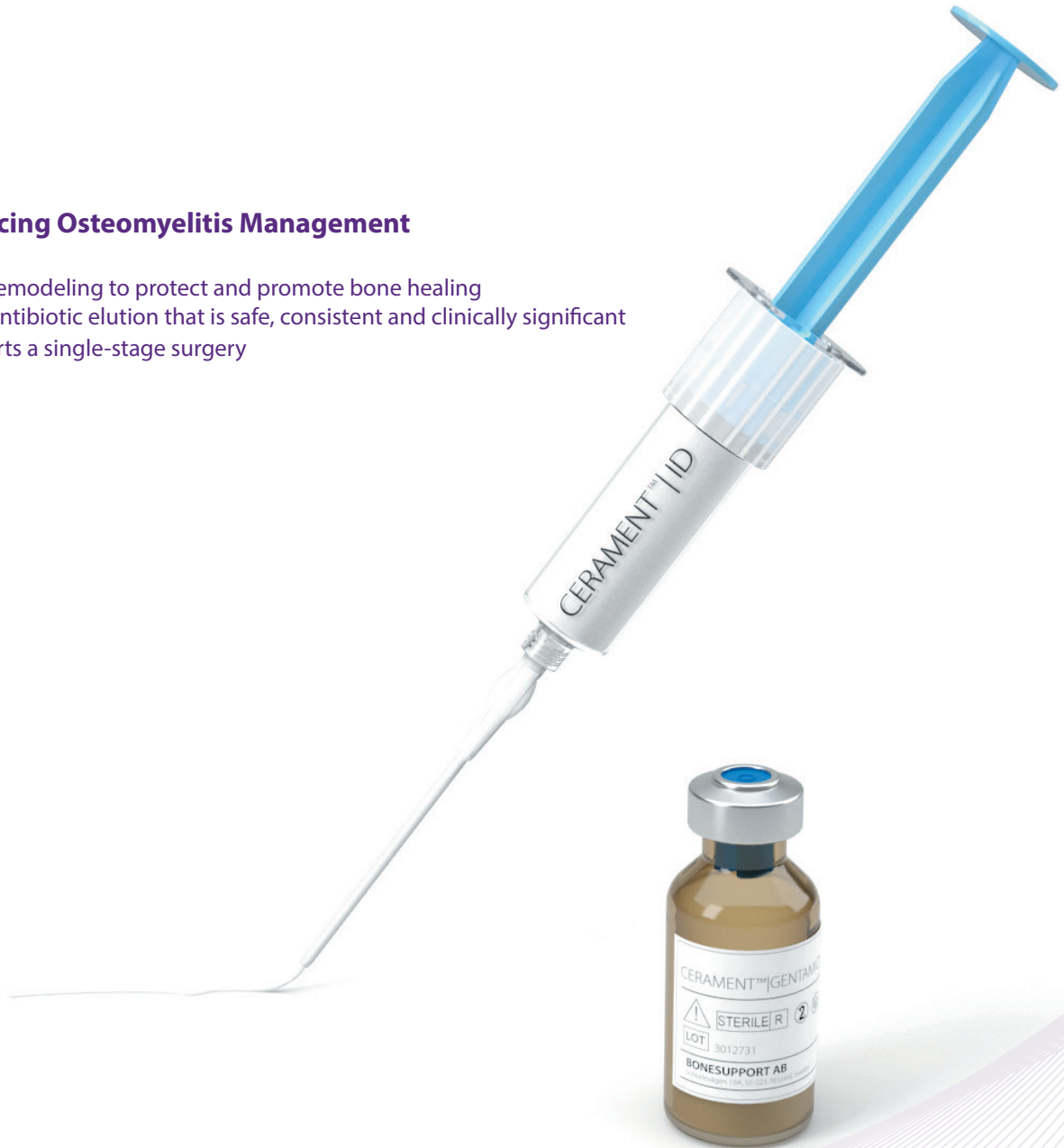Isolated Pathogens	Number of Patients
Staphylococcus aureus	4 (33%)
Escherichia coli	3 (25%)
Pseudomonas aeruginosa	2 (17%)

Poly-microbial infection	Number of Patients
P. aeruginosa with S. aureus	3 (25%)

3 patients (25%) had cultured organisms that were resistant to gentamicin using the EUCAST breaking points and there was no recurrence of infection.

Advancing Osteomyelitis Management

- Bone remodeling to protect and promote bone healing
- Local antibiotic elution that is safe, consistent and clinically significant
- Supports a single-stage surgery



TO ORDER

ORDER@BONESUPPORT.COM



BONESUPPORT AB
Ideon Science Park,
Scheelevägen 19
SE-223 70 Lund, Sweden

T: +46 46 286 53 70
F: +46 46 286 53 71
E: info@bonesupport.com
W: bonesupport.com

