



■ GENERAL ORTHOPAEDICS

Single-stage treatment of chronic osteomyelitis with a new absorbable, gentamicin-loaded, calcium sulphate/hydroxyapatite biocomposite

M. A. McNally,
J. Y. Ferguson,
A. C. K. Lau,
M. Diefenbeck,
M. Scarborough,
A. J. Ramsden,
B. L. Atkins

From Nuffield
Orthopaedic Centre,
Oxford University
Hospitals NHS
Foundation Trust,
Oxford, United
Kingdom

■ M. A. McNally, MD, FRCSEd, FRCS(Orth), Consultant in Limb Reconstruction Surgery, Honorary Senior Lecturer in Orthopaedic Surgery
■ J. Y. Ferguson, MB, BCh(Hons), MEd, FRCS(Orth), Specialty Trainee in Orthopaedics
■ A. C. K. Lau, MBBS, FRCSEd(Orth), Clinical Fellow in Limb Reconstruction
■ M. Diefenbeck, MD, PhD, Honorary Consultant in Orthopaedic Surgery
■ M. Scarborough, PhD, MRCP, FRCPath, Consultant in Infectious Diseases
■ B. L. Atkins, MBBS, MA, MSc, FRCPath, FRCP, Consultant in Microbiology and Infectious Diseases
■ A. J. Ramsden, MB, ChB, MD, FRCS (Plast), Consultant Plastic and Reconstructive Microsurgeon
Nuffield Orthopaedic Centre, The Bone Infection Unit, Oxford University Hospitals Foundation NHS Trust, Oxford OX3 7HE, UK.

Correspondence should be sent to Mr M. A. McNally; e-mail: martin.mcnally@ouh.nhs.uk

©2016 The British Editorial Society of Bone & Joint Surgery
doi:10.1302/0301-620X.98B9.38057 \$2.00

Bone Joint J
2016;98-B:1289–96.
Received 16 February 2016;
Accepted after revision 10 May 2016

A PROSPECTIVE SERIES OF 100 CASES

Aims

Chronic osteomyelitis may recur if dead space management, after excision of infected bone, is inadequate. This study describes the results of a strategy for the management of deep bone infection and evaluates a new antibiotic-loaded biocomposite in the eradication of infection from bone defects.

Patients and Methods

We report a prospective study of 100 patients with chronic osteomyelitis, in 105 bones. Osteomyelitis followed injury or surgery in 81 patients. Nine had concomitant septic arthritis. 80 patients had comorbidities (Cierny-Mader (C-M) Class B hosts). Ten had infected nonunions.

All patients were treated by a multidisciplinary team with a single-stage protocol including debridement, multiple sampling, culture-specific systemic antibiotics, stabilisation, dead space filling with the biocomposite and primary skin closure.

Results

Patients were followed up for a mean of 19.5 months (12 to 34). Infection was eradicated in 96 patients with a single procedure and all four recurrences were successfully managed with repeat surgery. Adverse events were uncommon, with three fractures, six wound leaks and three unrelated deaths. Outcome was not dependant on C-M host class, microbial culture, wound leakage or presence of nonunion.

Conclusion

This single-stage protocol, facilitated by the absorbable local antibiotic, is effective in the treatment of chronic osteomyelitis. It offers a more patient-friendly treatment compared with other published treatment options.

Cite this article: *Bone Joint J* 2016;98-B:1289–96.

Chronic osteomyelitis is a devastating complication after trauma or orthopaedic surgery.¹ Patients may present with multiple comorbidities, poor soft tissues and multi-resistant organisms, having endured prolonged unsuccessful treatment over many years.²⁻⁵

Staged surgical treatment is common, with repeated debridement and delayed skin closure.^{2,6-14} Further operations may be required to remove polymethylmethacrylate (PMMA) antibiotic-loaded beads or to reconstruct bone defects.^{15,16} Recently, negative pressure wound therapy (NPWT), has been combined with multiple debridement, increasing the number of revision procedures but not improving the rate of resolution of osteomyelitis.^{17,18}

There is now increasing interest in developing a one-stage approach, which might be

more patient friendly. This requires effective dead space management, to eradicate the infection and prevent the need for secondary bone grafting.

In animal studies, Branstetter et al¹⁹ showed that local antibiotics in calcium sulphate eradicated bacteria better after debridement when compared with calcium sulphate alone. Rand, Penn-Barwell and Wencke²⁰ confirmed that local delivery of antibiotics into an infected bone defect, with or without an implant, was superior to systemic antibiotics alone at 14 days after surgery. Xie et al²¹ compared debridement alone with bioglass, antibiotic-loaded calcium sulphate (CS) and antibiotic-loaded bioglass in a rabbit methicillin resistant *staphylococcus aureus* (MRSA) osteomyelitis model. Bioglass alone was no better than

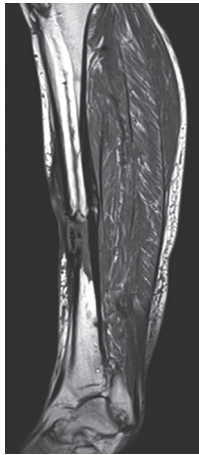


Fig. 1a

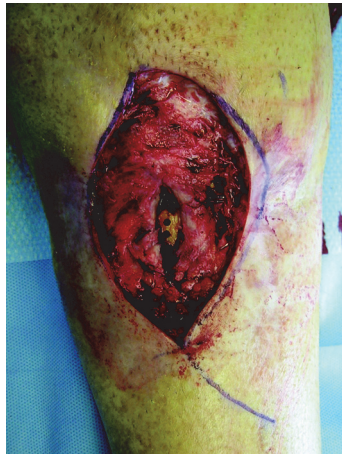

Fig. 1b

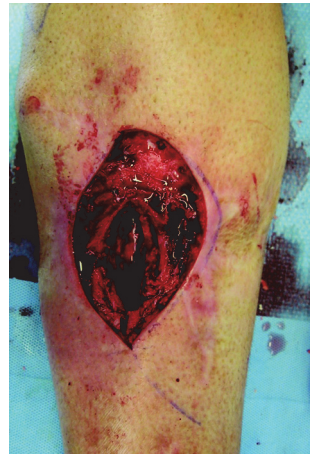

Fig. 1c

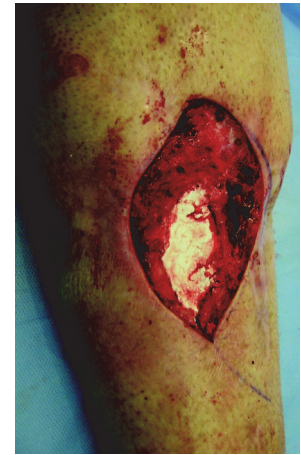

Fig. 1d

a) Sagittal MR image of the tibia, showing a mid-diaphyseal osteomyelitis with anterior sequestration after intramedullary nailing. The cortex had been drilled six years earlier in an attempt to drain infection; b) At operation, the anterior unstable skin and sinus was excised, revealing the dead cortical bone with visible drill holes with surrounding compromised, sclerotic bone and soft tissue; c) All dead bone and soft tissue has been excised back to healthy bleeding tissue. The medullary canal was opened proximally and distally. The cavity was then washed and packed with cotton gauze to dry the surface; d) 10 mls of CERAMENT G (Bonesupport, Lund, Sweden) were injected into the cavity, three minutes after the start of mixing. After 7 minutes, the material was compressed with a gauze swab to improve the contact at the bone surface. The material hardened over a duration of 10 to 15 minutes and the skin defect was covered with a free gracilis muscle flap and split skin graft.

debridement, but both antibiotic-loaded materials were highly effective. CS-based materials are effective for eradicating infection in humans,²²⁻²⁸ but bone formation in the defects caused after excision of infected bone is unreliable, with pathological fractures occurring in 5% to 8% of patients.^{24,26,27}

The combination of CS and hydroxyapatite (HA) in a synthetic, injectable composite is, however, more promising.^{29,30} The biphasic resorption of CS/HA forms an osteoconductive scaffold and leads to an early biological response.³¹ This combination may be both osteoinductive and osteoconductive³² and is now available loaded with gentamicin (175 mg gentamicin in 10 mls CS/HA: CERAMENT G; Bonesupport, Lund, Sweden). It has been shown that CERAMENT G injected into osteomyelitic bone voids, decreased the rate of infection and increased bone formation in a rat osteomyelitis model.³³

We present the first series of patients with chronic osteomyelitis treated with a one-stage surgical protocol, using CERAMENT G in dead space management.

Patients and Methods

Inclusion criteria. All patients presenting with possible Cierny-Mader (C-M) Type III (Localised) and Type IV (Diffuse) chronic osteomyelitis were recruited into this study.³⁴ The patients were assessed by both orthopaedic and plastic surgeons specialising in bone infections, as well as by a microbiologist/infectious disease physician.

Chronic osteomyelitis was defined as having symptoms for a minimum of six months with clinical and radiological features accompanied by at least one of the following: the presence of a sinus, an abscess or intra-operative pus, supportive histology, or two or more microbiological cultures

with indistinguishable organisms.⁷ When cultures were negative, a patient was only included in the study when there was positive histology, with the presence of a draining sinus or intra-operative pus. Infected nonunions were included if the bone loss was < 1cm at presentation. Exclusion criteria included diabetic foot infections, patients with calcium metabolism disorders or a known allergy to CS, HA or aminoglycosides and patients with renal failure.

A total of 106 consecutive patients were recruited between March 2013 and February 2015. However, six patients were excluded because intra-operative microbiological and histological samples did not meet the diagnostic criteria. The remaining 100 patients (65 male, 35 female) with infection involving 105 bones, were included. No patient was excluded due to known gentamicin allergy or renal compromise. Their mean age was 51.6 years (23 to 88). All patients were reviewed at a mean of 19.5 months (12 to 34), except one patient who died of a drug overdose five months into the study.

Data collection. Demographics, comorbidities, aetiology of infection, clinical features, diagnostic tests, antibiotic treatment choice and duration, were collected prospectively.

The extent of bony involvement (C-M anatomical type) was determined at operation. The host's physiological status was recorded at presentation as either Class A (no comorbidities), Class B^L (local compromise in the affected limb), Class B^S (systemic compromise) or Class B^{LS} (local and systemic comorbidities).³⁴ Radiological and microbiological outcomes were confirmed by two assessors who were not involved in the management of the patients.

Surgical management. All patients were treated according to a single-stage protocol for chronic osteomyelitis.^{2,35} Where possible, a tourniquet was used. Multiple deep intra-

Table I. Location of osteomyelitis by Cierny and Mader (C-M) stage, soft-tissue management and stabilisation method

Bone	Total	C-M stage*								Soft-tissue cover			Fixation		
		III A	III B ^L	III B ^S	III B ^{LS}	IV A	IV B ^L	IV B ^S	IV B ^{LS}	Direct closure	Local flap	Free flap	None	External fixation	Internal fixation
Tibia	38	7	14	4	9	1	1	1	1	21	4	13	32	6 [†]	
Femur	24	5	7	3	4		1	1	3	23	1		19	4 Mono [§]	1 IMN [‡]
Humerus	16	2	2	4	2		1	1	4	15		1	11	3 Mono [§]	2 Plates
Radius/ulna	10	4		4				1	1	10			10		
Calcaneum	3		2	1				1		2		1	3		
Clavicle	2			2						2			2		
Fibula	1				1							1	1		
Sacrum	1			1						1			1		
Scapula +humerus	1					1				1				1 Ilizarov	
Femur+tibia	1							1		1				1 Ilizarov	
Tibia+talus	3						1	1	1	1		2		2 Ilizarov	1 IMN [‡]
Total	100	18	25	19	16	2	4	5	11	77	5	18	79	17	4

* A, Normal host; B^L, Host with local compromise; B^S, Host with systemic compromise; B^{LS}, Host with local and systemic compromise

† 4 monolateral and 2 Ilizarov fixators

§ Monolateral fixator

‡ Intramedullary nail

operative samples were taken, using an established protocol.^{10,36,37} Sinus tracts were excised and infected implants removed with excision continuing until healthy, bleeding bone was exposed. After excision, the area was irrigated with 0.05% aqueous chlorhexidine solution and the cavity dried by packing with gauze. If instability was present, stabilisation was provided by external or internal fixation. After changing of drapes and gloves, the dry dead space was filled with CERAMENT G (Fig. 1). No additional material or antibiotic was added and primary skin closure was achieved either directly or by local or free microvascular muscle flaps.

Antibiotic management. Antibiotic therapy was stopped in all patients at least two weeks prior to surgery, provided it was safe to do so.^{27,38} During surgery, patients were given intravenous vancomycin (continued as 1 g every 12 hours initially) and meropenem (500 mg every eight hours initially) after samples had been taken. This empirical antibiotic regime (a glycopeptide and a carbapenem) has been shown to be effective against 96% of the isolated organisms in a similar heterogeneous cohort of patients with osteomyelitis.³⁷ Antibiotic treatment continued for six to 12 weeks based on the results of the final culture.

Outcome parameters. The primary outcome was eradication of infection at a minimum of one year after surgery. Failure of treatment was defined as recurrent infection with positive cultures from further radiologically guided aspiration or biopsy; recurrent sinus formation; further surgery performed for infection; or any patient requiring antibiotic treatment for persisting symptoms.²⁷

Secondary outcomes were death, need for re-operation, pathological fracture at the site of surgery and disturbance of wound healing.

Statistical analysis. Data were collated using Microsoft Excel (Redmond, Washington) and analysed with SPSS v20

(SPSS Inc., Chicago, Illinois). Patient data were regarded as non-parametric and groups were compared using the chi-squared test for low frequency variables. A p-value < 0.05 was considered significant.

Results

Patients. The C-M classification defined 78 patients as Type III and 22 as Type IV. A total of 80 patients (80%) were Class B hosts (Table I). Nine patients had septic arthritis of an adjacent joint (three shoulders, two elbows, three ankles, one wrist) and ten had infected nonunion (four tibiae, three femurs, three humeri). Chronic osteomyelitis most commonly followed a history of an open fracture or following fixation of closed fractures (71 patients). A total of 19 patients had haematogenous infection, six had infection after elective surgery (osteotomy, ligament repair, arthroscopy or fusion) and four followed a soft-tissue injury without a fracture.

The tibia, femur and humerus were the most commonly involved bones, with five patients having two bones involved (Table I).

A total of 21 patients required stabilisation and five patients were treated with primary joint fusion. Direct skin closure was possible in 77 patients, but five required a local flap and 18 needed free muscle flap reconstruction (Table I). All patients had primary skin closure. No wounds were left open after initial surgery and no second debridement was planned in any patient.

Microbiology. Staphylococci were the most common organism (41 cultures; 41.8%), with MRSA in six patients (Table II). *Proteus mirabilis* and *Pseudomonas spp* were more common in polymicrobial infection, often with a gram-positive organism, usually *Staphylococcus aureus*. A total of 16 patients cultured organisms which were shown to be gentamicin resistant using EUCAST breakpoints.³⁸ Of these,

Table II. Microbiological results by aetiology of infection

Aetiology of infection	Total	Post-fracture	Haematogenous	Infection after soft-tissue injury	Infection following elective surgery
Organisms					
MSSA	30	18 (1)	6	2	3
MRSA	6	3 (1)	1 (1)		
CoNS	5	3 (1)	1		
<i>Pseudomonas spp</i>	7	5 (1)		1	
<i>E. coli</i>	5	3 (1)		1	
<i>Enterobacter spp</i>	5	3 (1)			1
<i>Corynebacteria spp</i>	4	3			1
<i>Achromobacter spp</i>	3		(1)	1 (1)	
<i>Proteus spp</i>	4	4			
<i>Bacillus spp</i>	2	2			
<i>Streptococcus spp</i>	5	(5)			
<i>Bacteroides spp</i>	1	1			
<i>Enterococcus spp</i>	6	5			(1)
<i>Klebsiella spp</i>	4	2	(1)		1
<i>Morganella spp</i>	3	(2)			1
<i>Citrobacter</i>	2	1			1
<i>Propionobacteria spp</i>	1		1		
<i>Serratia spp</i>	1	(1)			
<i>Salmonella spp</i>	1		(1)		
<i>Clostridia spp</i>	1	(1)			
Polymicrobial	21	10(7)	(1)	1	1(1)

MSSA, methicillin sensitive *Staphylococcus aureus*; CoNS, coagulase negative *Staphylococci*; MRSA, methicillin resistant *Staphylococcus aureus*

Numbers in parentheses are organisms which exhibit gentamicin resistance

Table III. Details of recurrent infections

Case	Site	Aetiology	Cierny-Mader stage	Initial surgery	Days to recurrence	Initial microbiology	Recurrent microbiology	Revision treatment
1	Distal Radius	Fracture with ORIF	III A	Excision 4 mls CG	156	No growth	MSSA <i>Serratia marcescens</i>	Drainage of abscess only
2	Tibial diaphysis	Gunshot wound to tibia	III B ^L	Excision 30 mls CG Latissimus dorsi free flap	214	MSSA	MSSA <i>Streptococcus agalactiae</i>	Revision excision 20mls CG
3	Femur diaphysis	Open femoral fracture with ORIF	III B ^L	Excision 20 ml CG Monolateral external fixator	563	Resistant <i>Pseudomonas spp.</i>	Resistant <i>Pseudomonas spp.</i>	Revision excision with Amikacin in Calcium Sulphate
4	Calcaneum	Heel shift Osteotomy	III B ^L	Excision 6 mls CG Direct closure of previous ALT Flap	145	MSSA	MSSA	Revision excision 8mls CG Gracilis Muscle Flap

CG, CERAMENT G; MSSA, methicillin-sensitive *Staphylococcus aureus*; ALT, anterolateral fasciocutaneous thigh flap; ORIF, open reduction and internal fixation

some organisms exhibited intrinsic (*Salmonella enteritidis*, *streptococci*) and high level resistance (*enterococci*). Gentamicin resistance was just as likely to be present in patients with haematogenous infections (3/19; 15.8%) as in patients following trauma (13/81; 16%) (chi-squared test, $p = 0.978$). Gentamicin resistant organisms were more likely to be in polymicrobial infections (9/21; 42.8%) than in single isolates (7/79; 8.9%) (chi-squared test, $p < 0.001$).

Recurrence of infection. Infection was eradicated in 96 out of 100 patients by a single-stage operation. Recurrence

occurred in four patients (Table III). Recurrence was no more likely with a resistant organism (1/16; 6.25%) than after fully sensitive cultures (3/84; 3.6%; chi-squared test, $p = 0.62$). Physiological host class did not predict the likelihood of recurrence (1/20 Class A; 5% vs 3/80 Class B; 3.75%; chi-squared test, $p = 0.799$). At final follow-up, all four patients remained infection-free at 13, 16, 17 and 20 months after revision surgery.

All ten infected nonunions were infection-free at final follow-up; eight were united with planned primary surgery alone (Table IV).

Table IV. Summary of secondary complications (excluding recurrence of infection)

Case	Bone	Cierny-Mader stage	Complication	Timing	Treatment	Outcome
1	Humerus	III A	Fracture after high energy fall, with major rib fractures	4 wks	Conservative	Healed/good function
2	Tibia	IV B ^L	Undisplaced fracture after a fall while intoxicated	11 mths	Conservative	Healed/good function
3	Radius	IV B ^{LS}	Fracture after low energy fall	4 wks	Conservative (declined fixation)	Not united. Asymptomatic in frail patient
4	Tibia	III A	Sterile wound leakage	1 to 6 wks	Dressings	Healed/no recurrence
5	Radius	III B ^S	Sterile wound leakage	2 to 9 days	Dressings	Healed/no recurrence
6	Femur	III B ^L	Sterile wound drainage	1 to 11 wks	Dressings	Healed/no recurrence
7	Tibia	III B ^{LS}	Sterile wound drainage	1 to 4 mths	Dressings	Healed/no recurrence
8	Tibia	III A	Sterile wound drainage	1 to 4 wks	Dressings	Healed/no recurrence
9	Tibia	III B ^{LS}	Sterile wound drainage	1 to 8 wks	Dressings	Healed/no recurrence
10	Humerus Non-union	IV B ^{LS}	Persistent nonunion after monolateral fixation		Conversion to internal fixation with a plate	United/Infection-free at 19 mths
11	Intra-articular proximal tibia nonunion	IV B ^{LS}	Persistent nonunion		None	Patient considering endoprosthesis replacement. Infection-free at 31 mths
12	Calcaneum	III B ^L	Bulky fasciocutaneous flap interfering with shoe fitting		Liposuction at 1 yr after surgery	Healed/Infection-free at 23 mths
13	Tibia amputation stump	III B ^{LS}	Ulceration above tibia from inappropriate prosthetic use		Conversion of below-knee amputation to above-knee amputation	Healed/Infection-free at 15 mths

All five joint fusions healed with no recurrence of infection at final follow-up.

Complications. Three patients died of causes unrelated to the osteomyelitis or surgery. Table IV summarises the main complications and unplanned re-operations.

A total of 94 patients had normal wound healing. Six patients had white wound drainage which had the appearance of liquefied CS residue. It was managed expectantly with dressings and required no other intervention. Leakage was most common in distal tibial cases (4/6) when no muscle flap was used. No patient with early wound drainage developed a recurrence of infection.

A total of 11 patients had signs of minor extraosseous leakage of CERAMENT G into the surrounding soft tissues which was visible on the radiograph. This was not related to the volume of the material used, the site of infection or the soft-tissue cover. In ten of the 11 patients, this material was fully resorbed and all 11 patients remained asymptomatic. Extraosseous leaks occurred nine times in the first 50 patients, but only twice in the second 50, which may represent a learning experience in the handling of the material and meticulous closure over the bone.

Of note, there was no statistically significant difference in recurrence rate, fracture rate, wound leak or extraosseous collection between those with a history of a fracture and the remaining patients. Nor was there any difference between patients treated with flaps and those treated with direct wound closure, or with those with differing C-M stage, although the numbers with complications were small.

Discussion

In 1931, Kulowski, showed that Orr's method, (radical excision, immobilisation and open wound dressings), was successful in 74% of 130 patients with chronic osteomyelitis, at one year after surgery.³⁹ This was without antibiotics or skin closure.

Since then, principles of treatment have evolved which have confirmed the place of adequate excision and stabilisation but have also added careful diagnostic sampling, antimicrobial therapy, dead space management and soft-tissue closure.^{2,6-11,13,14,27,34,35,37,40} Despite these advances, there remains a significant risk of recurrence.

In recent years, staged surgery, involving repeated excisions, placement of PMMA-gentamicin loaded beads or rods, or irrigation systems and delayed skin closure, has been used to improve outcomes.^{8,9,12,14,15,18,41,42} However, PMMA carriers have to be removed, as they prevent bone ingrowth⁸ and can lead to antibiotic resistance.⁴³ Multi-stage surgery often requires prolonged hospital stay with high costs.⁵ Also outcomes have been variable, with infection recurrence rates commonly reported to be above 10%^{8,12,14,18,41,42} and sometimes as high as 45%.¹⁵ It is reported that immunocompromised patients with polymicrobial cultures tend to have worse outcomes with this treatment.^{5,14,35,44,45}

On the other hand, bioabsorbable antibiotic-impregnated materials offer the possibility of single-stage surgery, with reduced hospital stay and a more patient friendly approach to treatment. In this study, we were able to treat chronic osteomyelitis in all patients with a single operation. The low recurrence rate of 4% at a minimum of one year

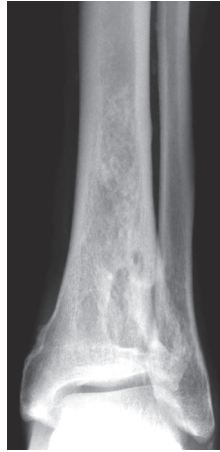

Fig. 2a

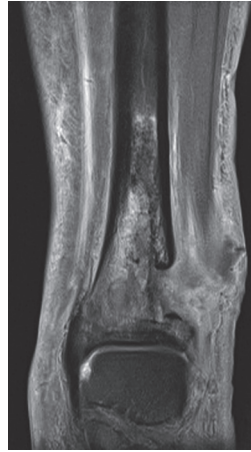

Fig. 2b

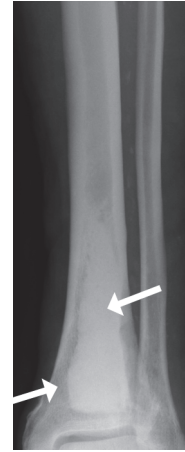


Fig. 2c

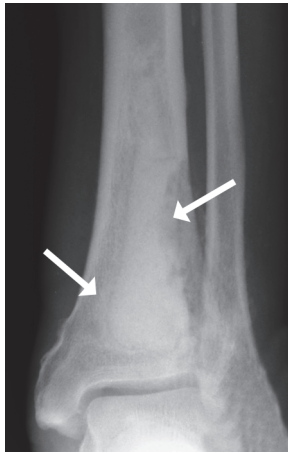


Fig. 2d

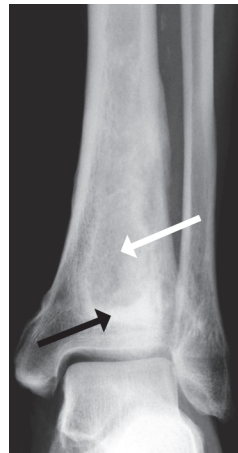

Fig. 2e

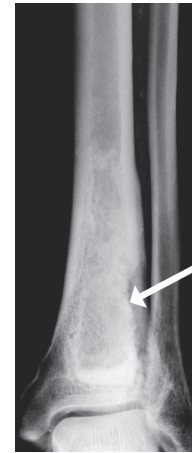


Fig. 2f

a) Pre-operative anteroposterior (AP) radiograph of the tibia with haematogenous osteomyelitis, present for more than ten years. There was a draining sinus and *Staphylococcus aureus* was cultured. The dead bone and surrounding cavity are visible in the lateral metaphysis; b) Coronal MR image demonstrating the lateral cortical defect, communicating with the skin sinus and central active infection; c) At surgery, the infected bone was removed and the cavity filled with 20 mls of CERAMENT G (Bonesupport, Lund, Sweden). This AP radiograph, taken three days after operation, shows the bone filling and good contact between the material and the bone surface. CERAMENT G is radio-opaque and initial radiographs will show a discreet margin around the material (arrows); d) At six weeks after surgery, the margin of the material is more diffuse and there is a 'reactive zone' seen around the CERAMENT G in the cancellous bone and on the surface of the material, medially; 'Halo Sign' (arrows); e) At six months after operation, there is residual, unremodelled material distally; 'Puddle Sign' (black arrow) and further peripheral bone changes. There is a reappearance of trabecular markings in the central zone (white arrow); f) At 18 months, the material has undergone further remodelling. There is increased density in the peripheral zone and the lateral cortex is more defined, compared with the six-week and six-month radiographs (arrow). Distally, the residual 'Puddle Sign' remains unremodelled.

follow-up, is encouraging as the series included many patients with medical comorbidities, polymicrobial cultures and segmental involvement. In previous studies, these features were associated with higher recurrence rates of up to 27%.^{7,14} In this study, we found no correlation between C-M physiological grade or polymicrobial infection and recurrence. This suggests that the single-stage approach with high bioavailability local antibiotics is a robust management strategy, applicable across a wide range of patients.

Recent papers describing similar cohorts using various methods of dead space management (CS, bioglass, PMMA rods, biocomposite granules, antibiotic-loaded demineralised bone matrix), have reported recurrence rates of 9% to 37.5% at a similar follow-up period.^{21,23,25-27,35,41,46} Our lower rate with CERAMENT G may reflect the increased ability of an injectable delivery system to coat the bone over areas which may harbour residual bacteria, or small fragments of biofilm. The high level of a bacteriocidal antibiotic from CERAMENT G acts at an important time, when most

residual bacteria will be in planktonic form, following adequate debridement.

The use of implanted local antibiotics removes concerns about compliance with antibiotic therapy and systemic toxicity. CERAMENT G delivers a burst of gentamicin with high local concentrations, around 100 times above the minimal inhibitory concentration (MIC) for gentamicin sensitive *Staphylococcus aureus* or *Pseudomonas* species in *in vitro* testing.⁴⁷ Rapid dissolution prevents a prolonged period of low-level antibiotic release, thus reducing the risk of gentamicin resistance.^{43,48,49}

In this study we successfully treated bacteria which were gentamicin resistant on laboratory testing. Resistance reporting is based on exposing bacteria to levels of antibiotic, which can be given systemically without toxicity. The survivability of bacteria when exposed to very high levels of antibiotics, up to 100 times above serum concentrations, is unknown.

Previous studies on antibiotic-loaded CS, have reported prolonged wound drainage affecting 15% to 32% of patients.^{26,27,35,50,51} In our series, wound leakage was infrequent and was mainly related to poor skin cover around the distal tibia. In all patients, we managed wound or extraosseous leaks expectantly, providing the patient was well. We do not believe that these leaks are an indication for re-operation and we found that it had no relationship with later recurrence of infection. This has also been described for other absorbable antibiotic carriers.^{27,35}

The low fracture rate in our study may reflect the higher stability achieved with an injectable *in situ* hardening material. The compressive strength of CERAMENT G is similar to that of cancellous bone in *in vitro* biomechanical testing.³¹ The inclusion of HA, which is not passively dissolved, may provide a longer-lasting scaffold for bone formation. Serial radiographs over the follow-up period demonstrated bone remodelling in the majority of patients. Bone formation appears to progress from the periphery of the material (Fig. 2). Progressive remodelling is governed by Wolff's law⁵² and will stop once sufficient bone has been formed to cope with daily load bearing. It is unlikely that large central medullary zones will fill with new bone after cortical integrity has been restored.

This study is limited by the relatively short follow-up and by patient selection. We have not investigated this material in large segmental defects and would not recommend its use for this indication without further study. Our limited clinical experience suggests that CERAMENT G would not have adequate mechanical strength to support a segmental defect without supplementary fixation.

There are many important principles of treating chronic osteomyelitis, including: obtaining multiple bacteriological samples, performing a thorough debridement with metalwork removal, ensuring adequate osseous stabilisation, eliminating the dead space and providing sufficiently vascularised soft-tissue cover. We accept that the low recurrence rate of this study is not solely due to the CERAMENT G. In our Institution, we have previously used different types of

biodegradable antibiotic carriers as adjuncts in the treatment of chronic osteomyelitis in the same surgical protocol. We have previously described our experience of using calcium sulphate pellets with tobramycin in 195 patients, with an infection recurrence rate of 9.3% and an associated wound leak rate of 15.4%, which is higher than the recurrence rate and wound leak rate in this series.²⁷

In conclusion, we report a large series of patients, managed with a single-stage protocol, facilitated by the use of CERAMENT G as a bioabsorbable dead space filler. This protocol delivered low recurrence rates with few re-operations or complications over a one- to three-year follow-up period. Our initial experience shows that this offers a patient-friendly treatment which merits further study.



Take home message:

This single-stage protocol, facilitated by the absorbable local antibiotic, is effective in the treatment of chronic osteomyelitis. It offers a more patient-friendly treatment compared with other published treatment options.

Author contributions:

M. A. McNally: Study design, Data collection and analysis, Writing the paper, Performing surgery.

J. Y. Ferguson: Data collection and analysis, Writing the paper, Performing surgery.

M. Diefenbeck: Data collection and analysis, Writing the paper.

A. Lau: Data collection.

M. Scarborough: Study design, Editing the paper.

A. J. Ramsden: Performed surgery, Editing the paper.

B. L. Atkins: Study design, Data analysis, Editing the paper.

One author of this study (JYF) was partly supported by an unrestricted research grant from Bonesupport AB, Lund, Sweden.

The author or one or more of the authors have received or will receive benefits for personal or professional use from a commercial party related directly or indirectly to the subject of this article.

This article was primary edited by S. P. F. Hughes and first proof edited by G. Scott.

References

1. Salvana J, Rodner C, Browner BD, et al. Chronic osteomyelitis: results obtained by an integrated team approach to management. *Conn Med* 2005;69:195–202.
2. McNally M, Nagarajah K. Osteomyelitis. *Orthop Trauma* 2010;24:416–429.
3. Romanò CL, Romanò D, Logoluso N, Drago L. Bone and joint infections in adults: a comprehensive classification proposal. *Eur Orthop Traumatol* 2011;1:207–217.
4. Berendt AR, McNally M. Osteomyelitis. In: Warrell DA, Cox TM, Firth JD, eds. *Oxford Textbook of Medicine*. Oxford: Oxford University Press, 2010:3788–3795.
5. McNally M, Sendi P. Implant-Associated osteomyelitis of long bones. In: Zimmerli W, ed. *Bone and Joint Infections: From Microbiology to Diagnostics and Treatment*. Chichester, West Sussex: John Wiley & Son, 2014:303–323.
6. Cierny G III. Chronic osteomyelitis: results of treatment. *Instr Course Lect* 1990;39:495–508.
7. Cierny G III, DiPasquale D. Treatment of chronic infection. *J Am Acad Orthop Surg* 2006;14:S105–S110.
8. Walenkamp GH, Kleijn LL, de Leeuw M. Osteomyelitis treated with gentamicin-PMMA beads: 100 patients followed for 1-12 years. *Acta Orthop Scand* 1998;69:518–522.
9. McNally MA, Small JO, Tofighi HG, Mollan RA. Two-stage management of chronic osteomyelitis of the long bones. The Belfast technique. *J Bone Joint Surg [Br]* 1993;75-B:375–380.
10. Spangehl MJ, Masri BA, O'Connell JX, Duncan CP. Prospective analysis of preoperative and intraoperative investigations for the diagnosis of infection at the sites of two hundred and two revision total hip arthroplasties. *J Bone Joint Surg [Am]* 1999;81-A:672–683.
11. Krenn V, Morawietz L, Perino G, et al. Revised histopathological consensus classification of joint implant related pathology. *Pathol Res Pract* 2014;210:779–786.

12. **Evans RP, Nelson CL.** Gentamicin-impregnated polymethylmethacrylate beads compared with systemic antibiotic therapy in the treatment of chronic osteomyelitis. *Clin Orthop Relat Res* 1993;295:37–42.
13. **Ilizarov GA.** The principles of the Ilizarov method. *Bull Hosp Jt Dis Orthop Inst* 1988;48:1–11.
14. **Lazzarini L, Mader JT, Calhoun JH.** Osteomyelitis in long bones. *J Bone Joint Surg [Am]* 2004;86-A:2305–2318.
15. **Cho SH, Song HR, Koo KH, Jeong ST, Park YJ.** Antibiotic-impregnated cement beads in the treatment of chronic osteomyelitis. *Bull Hosp Jt Dis* 1997;56:140–144.
16. **Tiemann AH, Schmidt HGK, Braunschweig R, Hofmann GO.** Strategies for the analysis of osteitic bone defects at the diaphysis of long bones. *Strategies Trauma Limb Reconstr* 2009;4:13–18.
17. **Diefenbeck M, Mennenga U, Gückel P, et al.** Vacuum-assisted closure therapy for the treatment of acute postoperative osteomyelitis. *Z Orthop Unfall* 2011;149:336–341. (In German).
18. **Timmers MS, Graafland N, Bernards AT, et al.** Negative pressure wound treatment with polyvinyl alcohol foam and polyhexanide antiseptic solution instillation in posttraumatic osteomyelitis. *Wound Repair Regen* 2009;17:278–286.
19. **Branstetter JG, Jackson SR, Haggard WO, Richelsoph KC, Wenke JC.** Locally-administered antibiotics in wounds in a limb. *J Bone Joint Surg [Br]* 2009;91-B:1106–1109.
20. **Rand BC, Penn-Barwell JG, Wenke JC.** Combined local and systemic antibiotic delivery improves eradication of wound contamination: an animal experimental model of contaminated fracture. *Bone Joint J* 2015;97-B:1423–1427.
21. **Xie Z, Liu X, Jia W, et al.** Treatment of osteomyelitis and repair of bone defect by degradable bioactive borate glass releasing vancomycin. *J Control Release* 2009;139:118–126.
22. **Chang W, Colangeli M, Colangeli S, et al.** Adult osteomyelitis: debridement versus debridement plus Osteoset T pellets. *Acta Orthop Belg* 2007;73:238–243.
23. **Turner TM, Urban RM, Hall DJ, et al.** Local and systemic levels of tobramycin delivered from calcium sulfate bone graft substitute pellets. *Clin Orthop Relat Res* 2005;437:97–104.
24. **Gitelis S, Brebach GT.** The treatment of chronic osteomyelitis with a biodegradable antibiotic-impregnated implant. *J Orthop Surg (Hong Kong)* 2002;10:53–60.
25. **McKee MD, Wild LM, Schemitsch EH, Waddell JP.** The use of an antibiotic-impregnated, osteoconductive, bioabsorbable bone substitute in the treatment of infected long bone defects: early results of a prospective trial. *J Orthop Trauma* 2002;16:622–627.
26. **McKee MD, Li-Bland EA, Wild LM, Schemitsch EH.** A prospective, randomized clinical trial comparing an antibiotic-impregnated bioabsorbable bone substitute with standard antibiotic-impregnated cement beads in the treatment of chronic osteomyelitis and infected nonunion. *J Orthop Trauma* 2010;24:483–490.
27. **Ferguson JY, Dudareva M, Riley ND, et al.** The use of a biodegradable antibiotic-loaded calcium sulphate carrier containing tobramycin for the treatment of chronic osteomyelitis: a series of 195 cases. *Bone Joint J* 2014;96-B:829–836.
28. **Nelson CL, McLaren SG, Skinner RA, et al.** The treatment of experimental osteomyelitis by surgical debridement and the implantation of calcium sulfate tobramycin pellets. *J Orthop Res* 2002;20:643–647.
29. **Nilsson M, Zheng MH, Tägil M.** The composite of hydroxyapatite and calcium sulphate: a review of preclinical evaluation and clinical applications. *Expert Rev Med Devices* 2013;10:675–684.
30. **Iundusi R, Gasbarra E, D'Arienzo M, Piccioli A, Tarantino U.** Augmentation of tibial plateau fractures with an injectable bone substitute: CERAMENT™. Three year follow-up from a prospective study. *BMC Musculoskelet Disord* 2015;16:115.
31. **Nilsson M, Wang J-S, Wielanek L, Tanner KE, Lidgren L.** Biodegradation and biocompatibility of a calcium sulphate-hydroxyapatite bone substitute. *J Bone Joint Surg [Br]* 2004;86-B:120–125.
32. **Raina D, Gupta A, Petersen M, et al.** A biphasic bone substitute with gentamycin regenerates bone in osteomyelitis with muscle acting as an osteoinductive niche. *Bone Joint J Orthopaedic Proceedings Supplement* 2015;97(Suppl 16):24.
33. **Dvorzhinskiy A, Perino G, Chojnowski R, et al.** Cerament bone void filler with gentamicin increases bone formation and decreases detectable infection in a rat model of debrided osteomyelitis. *Bone Joint J Proc Suppl* 2015;97(Suppl 16):9.
34. **Cierny G III, Mader JT, Penninck JJ.** A clinical staging system for adult osteomyelitis. *Clin Orthop Relat Res* 2003;414:7–24.
35. **Romano CL, Logoluso N, Meani E, et al.** A comparative study of the use of bioactive glass S53P4 and antibiotic-loaded calcium-based bone substitutes in the treatment of chronic osteomyelitis: a retrospective comparative study. *Bone Joint J* 2014;96-B:845–850.
36. **Atkins BL, Athanasou N, Deeks JJ, et al.** Prospective evaluation of criteria for microbiological diagnosis of prosthetic-joint infection at revision arthroplasty. The OSIRIS Collaborative Study Group. *J Clin Microbiol* 1998;36:2932–2939.
37. **Sheehy SH, Atkins BA, Bejon P, et al.** The microbiology of chronic osteomyelitis: prevalence of resistance to common empirical anti-microbial regimens. *J Infect* 2010;60:338–343.
38. **No authors listed.** Clinical Breakpoints. http://www.eucast.org/clinical_breakpoints/ (date last accessed 18 May 2016).
39. **Kulowski J.** The Orr treatment of osteomyelitis and allied suppurative processes. *J Bone Joint Surg [Am]* 1931;13-A:538–562.
40. **Bose D, Kugan R, Stubbs D, McNally M.** Management of infected nonunion of the long bones by a multidisciplinary team. *Bone Joint J* 2015;97-B:814–817.
41. **Kanakaris N, Gudipati S, Tosounidis T, et al.** The treatment of intramedullary osteomyelitis of the femur and tibia using the Reamer-Irrigator-Aspirator system and antibiotic cement rods. *Bone Joint J* 2014;96-B:783–788.
42. **Caesar BC, Morgan-Jones RL, Warren RE, et al.** Closed double-lumen suction irrigation in the management of chronic diaphyseal osteomyelitis: long-term follow-up. *J Bone Joint Surg [Br]* 2009;91-B:1243–1248.
43. **Neut D, van de Belt H, van Horn JR, van der Mei HC, Busscher HJ.** Residual gentamicin-release from antibiotic-loaded polymethylmethacrylate beads after 5 years of implantation. *Biomaterials* 2003;24:1829–1831.
44. **Zimmerli W, Sendi P.** Pathogenesis of implant-associated infection: the role of the host. *Semin Immunopathol* 2011;33:295–306.
45. **Lew DP, Waldvogel FA.** Osteomyelitis. *Lancet* 2004;364:369–379.
46. **Fleiter N, Walter G, Bösebeck H, et al.** Clinical use and safety of a novel gentamicin-releasing resorbable bone graft substitute in the treatment of osteomyelitis/osteitis. *Bone Joint Res* 2014;3:223–229.
47. **No authors listed.** Bonesupport. Gentamicin release in vitro from setting CERAMENT™|G paste. Data on file BONESUPPORT; Sweden, report S009/2012.
48. **Anagnostakos K, Hitzler P, Pape D, Kohn D, Kelm J.** Persistence of bacterial growth on antibiotic-loaded beads: is it actually a problem? *Acta Orthop* 2008;79:302–307.
49. **Walsh C.** Molecular mechanisms that confer antibacterial drug resistance. *Nature* 2000;406:775–781.
50. **Borrelli J Jr, Prickett WD, Ricci WM.** Treatment of nonunions and osseous defects with bone graft and calcium sulfate. *Clin Orthop Relat Res* 2003;411:245–254.
51. **McNally M, Ferguson J, Kendall J, et al.** A comparative study of three bioabsorbable antibiotic carriers in chronic osteomyelitis: 313 patients with minimum one-year follow-up. *Bone Joint J Proc Suppl* 2015;97(Suppl 16):21–22.
52. **Wolff J.** Ueber die innere Architectur der Knochen und ihre Bedeutung für die Frage vom Knochenwachstum. *Virchows Arch Pathol Anat Physiol* 1870;50:389–450.