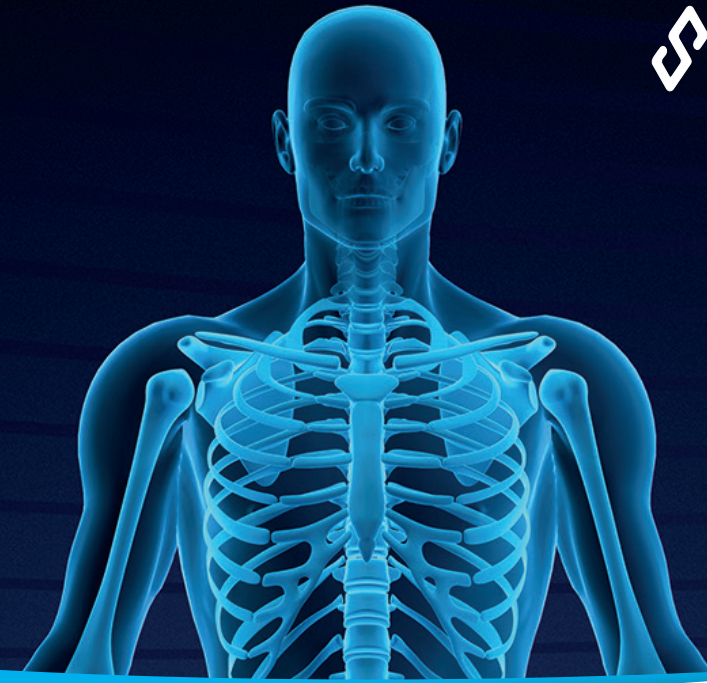

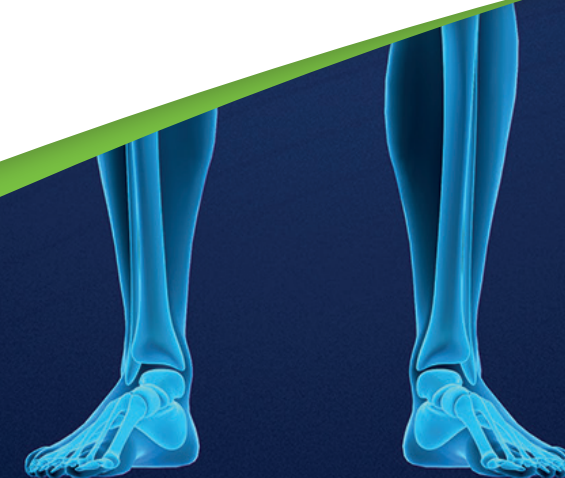


## Case Report :

Management of a Calcaneal Non-Union and Sub-Talar Joint Arthrodesis from a Calcaneal Fracture with Arthrodesis with **CERAMENT®** BONE VOID FILLER

Jeffrey C. Karr, DPM

Lakeland Regional Medical Center, Lakeland, Florida, U.S.A.



## Management of a Calcaneal Non-Union and Sub-Talar Joint Arthrosis from a Calcaneal Fracture with Arthrodesis with CERAMENT®|BONE VOID FILLER

### DIAGNOSIS

- Patient presented with a right painful rear-foot following bilateral calcaneal fracture management after falling from a height of 12 feet.
- The patient's lower extremity arterial circulation had no significant stenotic disease.
- Her past medical history was significant for hypertension and nicotine dependency.

### TREATMENT

- The initial bilateral external fixators were removed at eight weeks with minimal initial discomfort. After four weeks of physical therapy, the patient started to experience progressively more pain in the right rear-foot. This increased pain was unresponsive to continued physical therapy, arthrocentesis, and NSAID therapy. Radiograph and CT evaluation revealed a significant calcaneal fracture non-union and sub-talar joint arthrodesis. A bone stimulator was used for eight weeks without clinical improvement. The patient continued to smoke during the entire treatment process.

### Secondary Treatment:

- Open calcaneal non-union management and sub-talar joint arthrodesis with circular external fixation. The calcaneal non-union was subject to resection with a substantial amount of the non-union fibrous tissue resected back into the calcaneal body. Opposing facets of the sub-talar joint were then resected to healthy cancellous bone. The calcaneal body space at the area of the resected non-union was filled with CERAMENT®|BONE VOID FILLER. Then the opposing sub-talar joint surfaces, after they were placed in opposition and held with temporary fixation, were also filled with CERAMENT®|BONE VOID FILLER.

### OUTCOME

- The patient had an unremarkable post-operative course. The external fixator was removed at eight weeks with initiation of physical therapy. The patient progressed well with consolidation of the calcaneal non-union and the sub-talar joint arthrodesis.

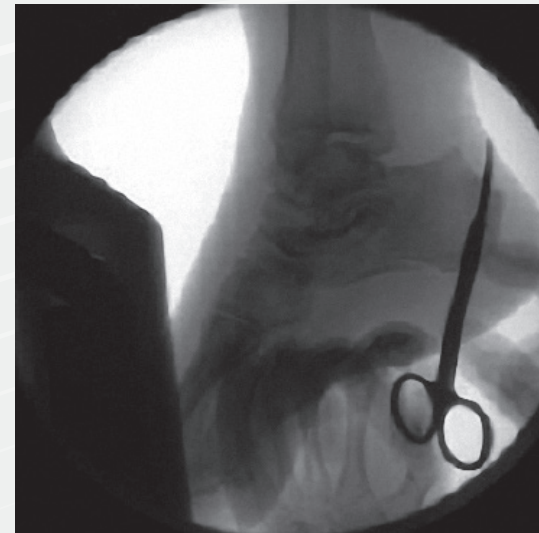


Figure 1. Initial lateral imaging of the fracture.

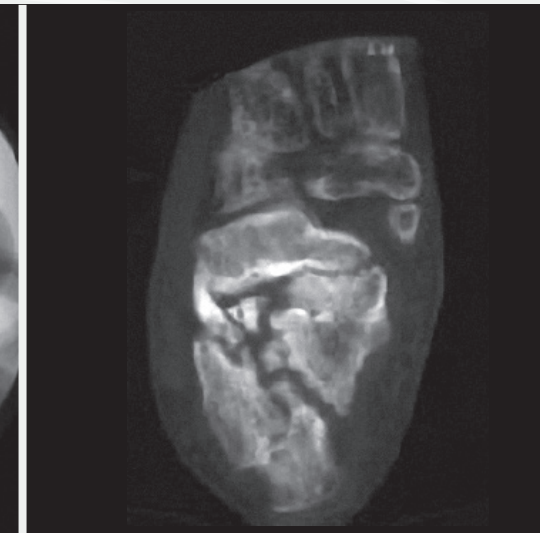


Figure 2. Foot CT of the initial fracture.

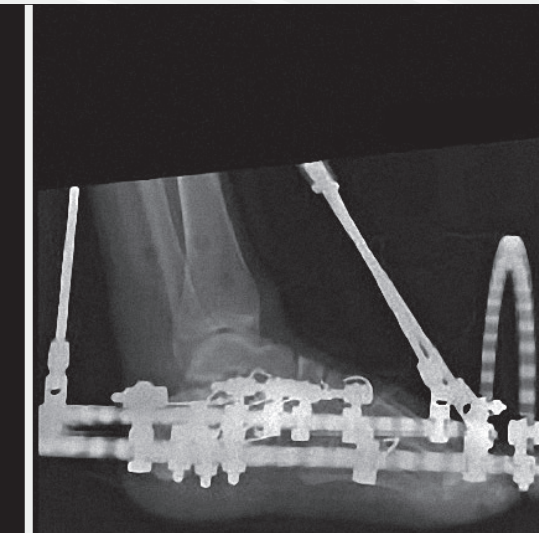


Figure 3. Initial calcaneal fracture.

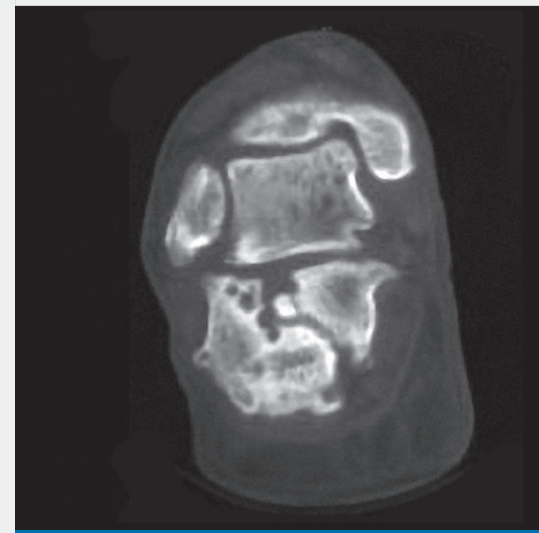


Figure 4. Foot CT of the non-union.

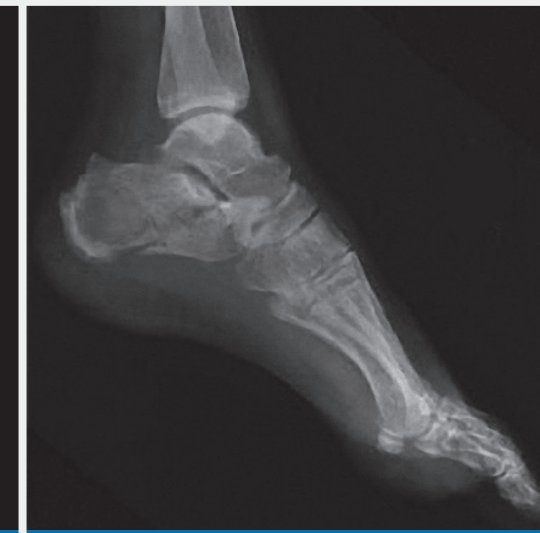

Figure 5. Foot radiograph of the non-union.

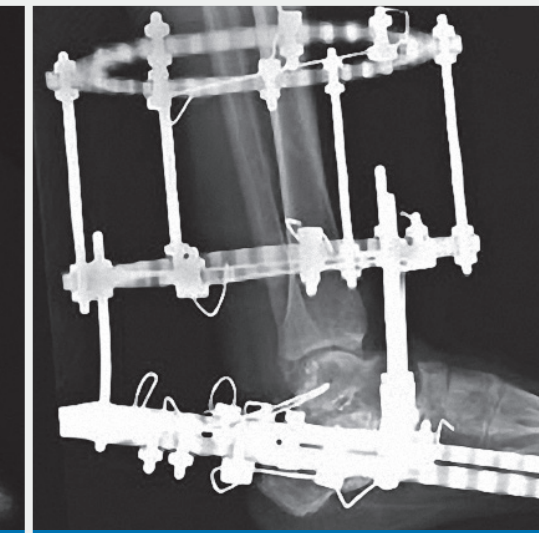


Figure 6. CERAMENT® placement for nonunion and arthrodesis management.

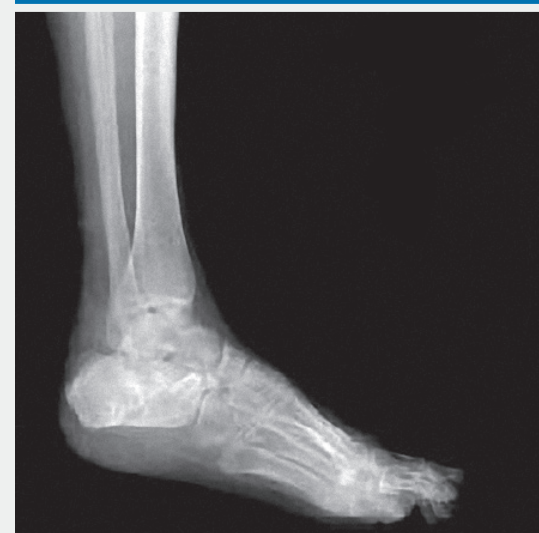

Figure 7. Final post-operative radiograph.