

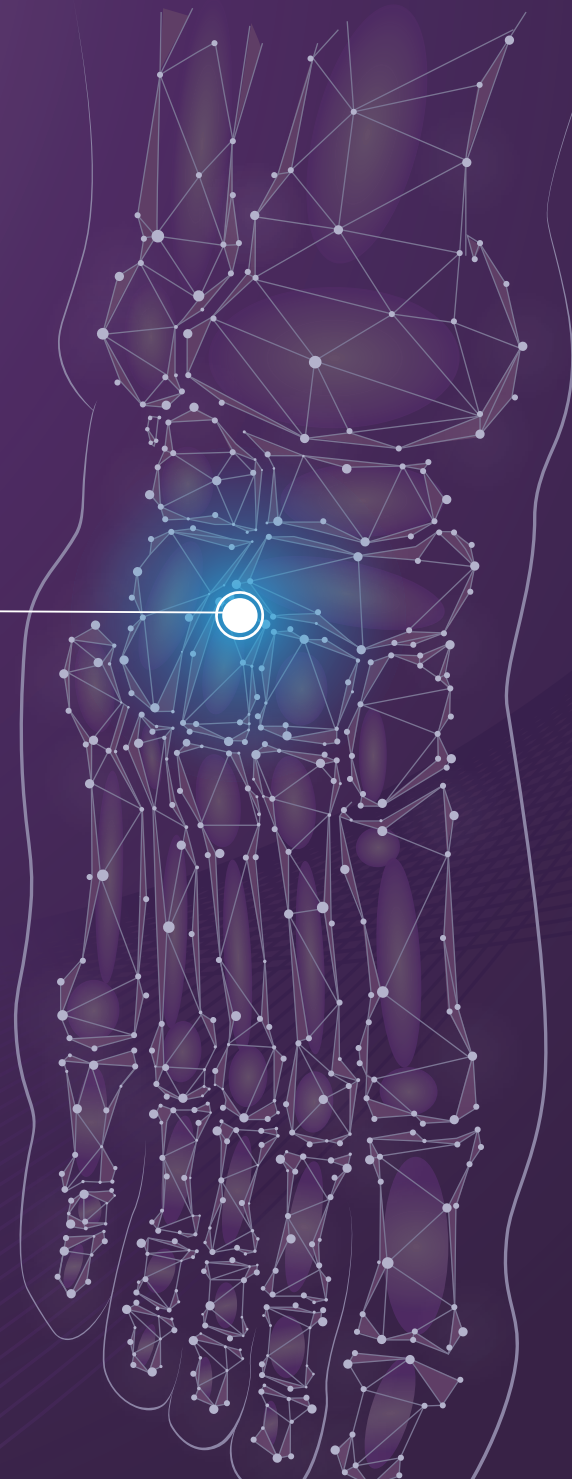
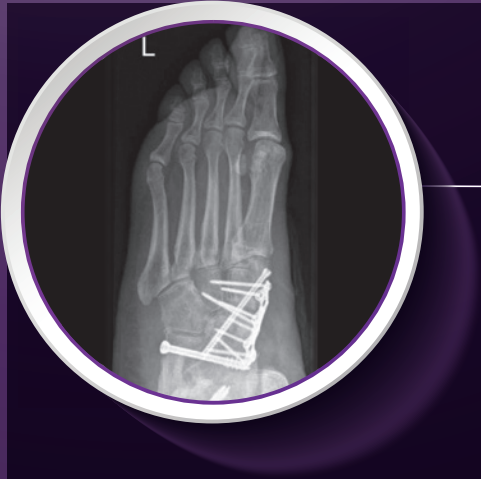CERAMENT® G
with Gentamicin

CASE REPORT

Medical Education Series

Management Of Infected Double Foot Arthrodesis 5 MONTHS FOLLOW-UP

DR. DIRK STEINHAGEN
Germany



DIAGNOSIS

64 year old

Patient had pes planus (flat foot), treated by arthrodesis of the talonavicular joint and subtalar joint. Some redness and swelling was initially noted but this settled without therapeutic intervention.

Three months later, infection with Staph aureus was confirmed and a CT scan showed arthrodesis, but with significant osteolysis present around the metalwork (Figs. 1 & 2).

TREATMENT

All metalwork was removed, a thorough debridement was carried out and three Septopal® chains (containing gentamicin) were inserted in the first part of a two-stage procedure. The patient was given systematic cefazolin.

During outpatient follow up the patient had clear wound secretion and primary healing of the wound with negative pressure wound therapy. 5 weeks post-operatively, the wound had completely healed and the patient had normalized inflammatory markers. Drain tubes were placed and the wound closed in layers.

During the second stage, the Septopal® chains were removed, another debridement was carried out and the remaining defects filled with 10mL of CERAMENT® G (Fig. 3).

OUTCOME

The patient had white wound drainage post-operatively but the wound healed with negative pressure wound therapy, and the patient was allowed to partially weight bear using a walker.

After 6 weeks, the patient was fully weight bearing.

At 5 months post-operatively, bone remodeling can be seen on the X-rays where CERAMENT® G was injected (Figs. 4 & 5), and the patient is pain and infection-free, with a complete return to normal activity and footwear (Figs. 6 & 7).

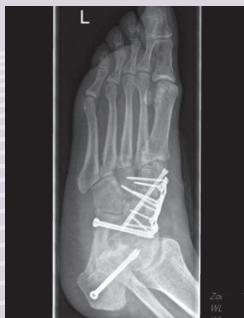

Figure 1

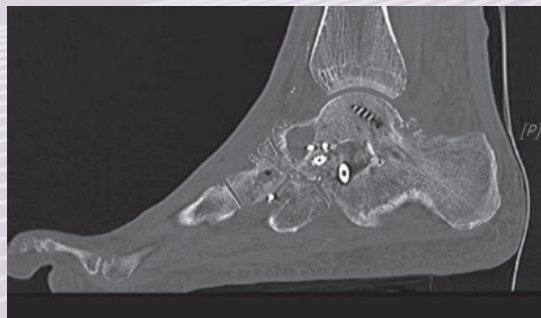


Figure 2

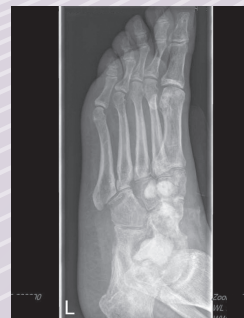

Figure 3

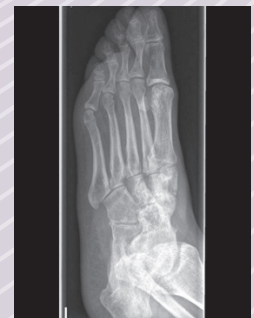

Figure 4

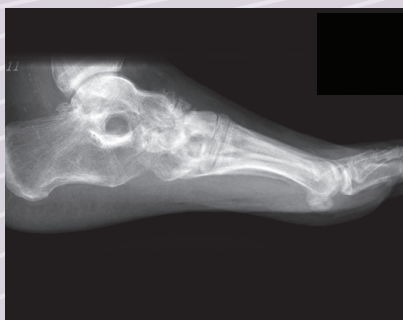

Figure 5

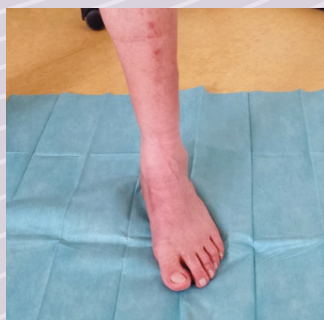

Figure 6

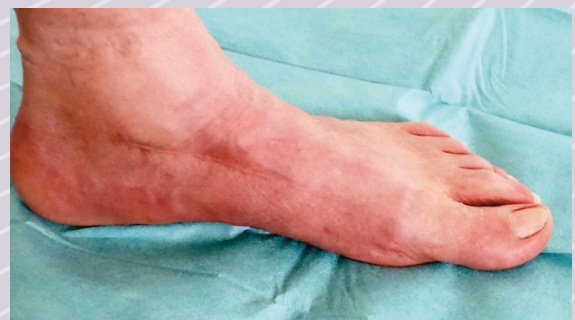

Figure 7